

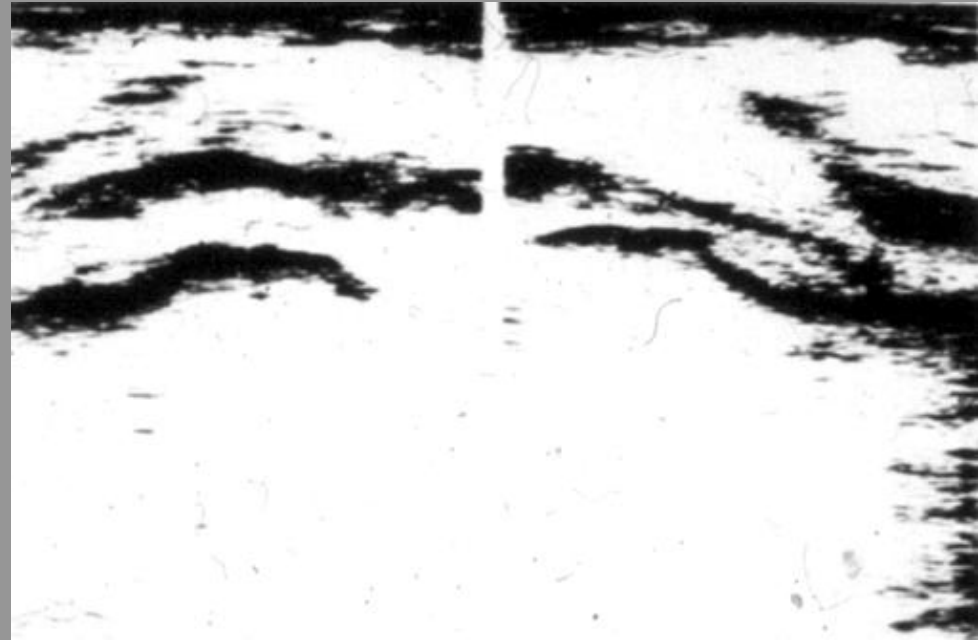
Transient synovitis of the hip joint
Perthes' disease
Slipped capital femoral epiphysis
Coxa vara



University of Debrecen
Department of
Orthopaedic Surgery

Transient synovitis of the hip joint

- 2-14 years of age
- male : female = 1:1
- sudden
hip/thigh/knee pain
- previous upper
airway infection
- non purulent coxitis



Transient synovitis of the hip joint

Differential diagnosis from purulent arthritis:

- NO FEVER
- CRP

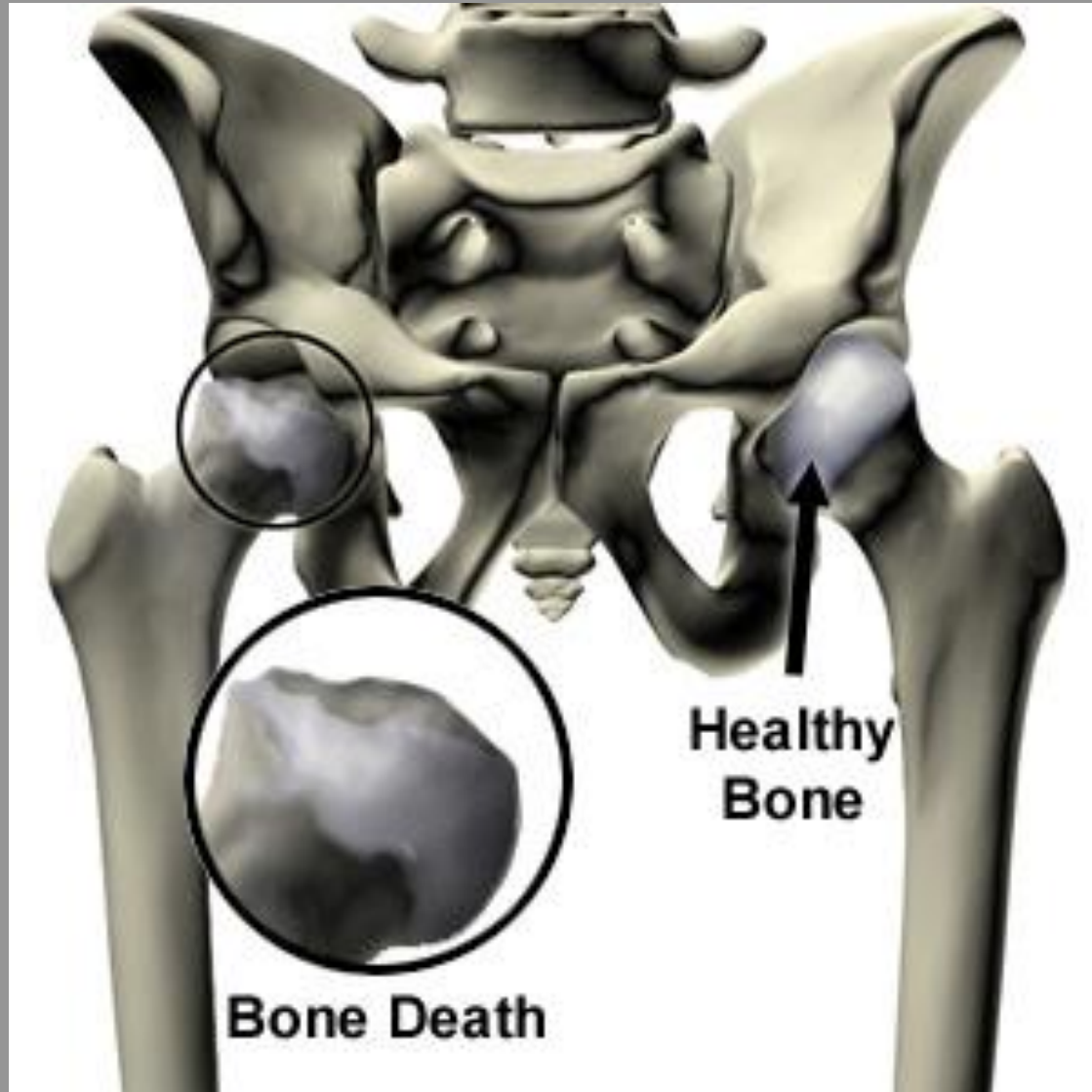
Treatment:

- Non-steroid anti-inflammatory drug
- Rest


Follow up:

X-ray 3 months later => Perthes' disease

Legg-Calve-Perthes' disease



Legg-Calve-Perthes' disease



Boston, USA

Berck, France

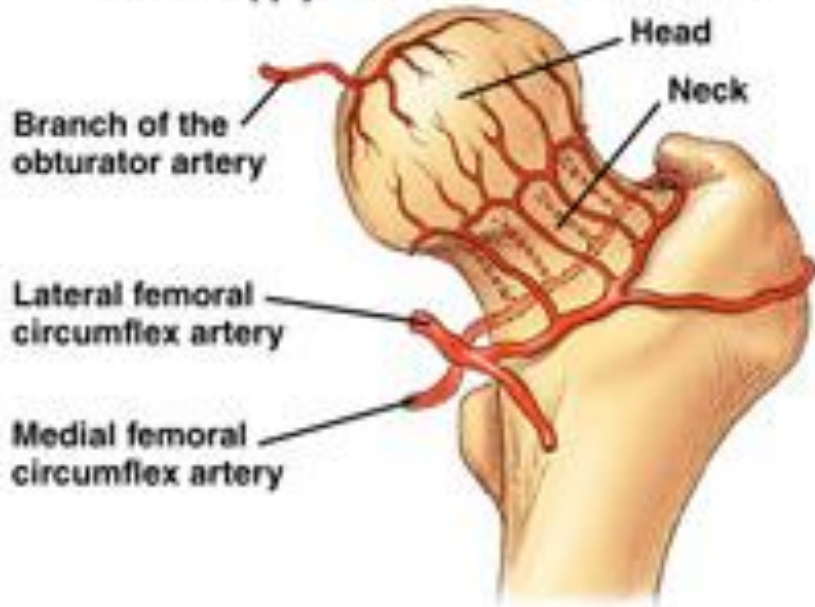
Tübingen, Germany

Legg-Calve-Perthes' disease

- 3-13 years of age
- incidence: 0,1-1%
- male : female = 3:1
- 15% bilateral
- duration: 3-5 years

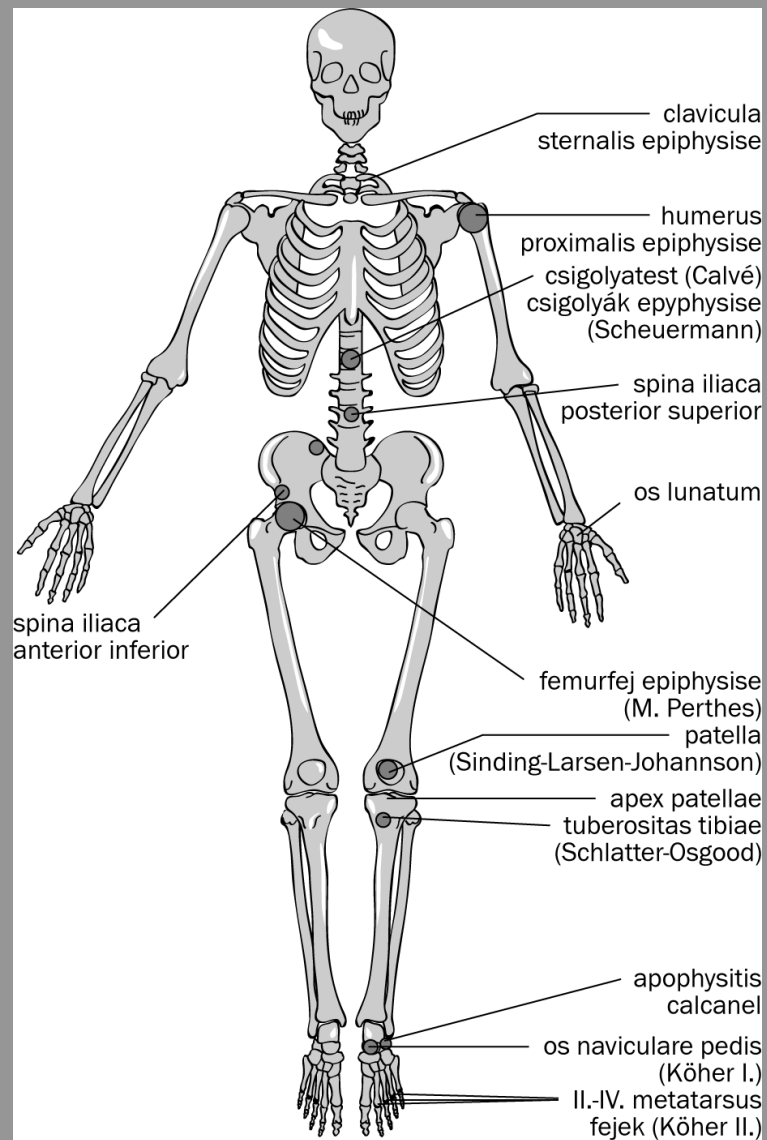
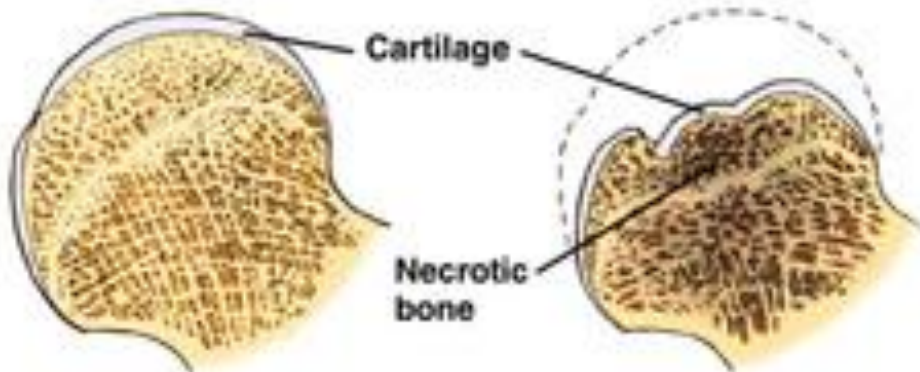


Blood Supply to Head and Neck of Femur



Normal Head

Avascular Necrosis Head



Legg-Calve-Perthes' disease

- intermittent pain
- decreased internal rotation
(abduction, extension)
- muscle atrophy
- leg length discrepancy

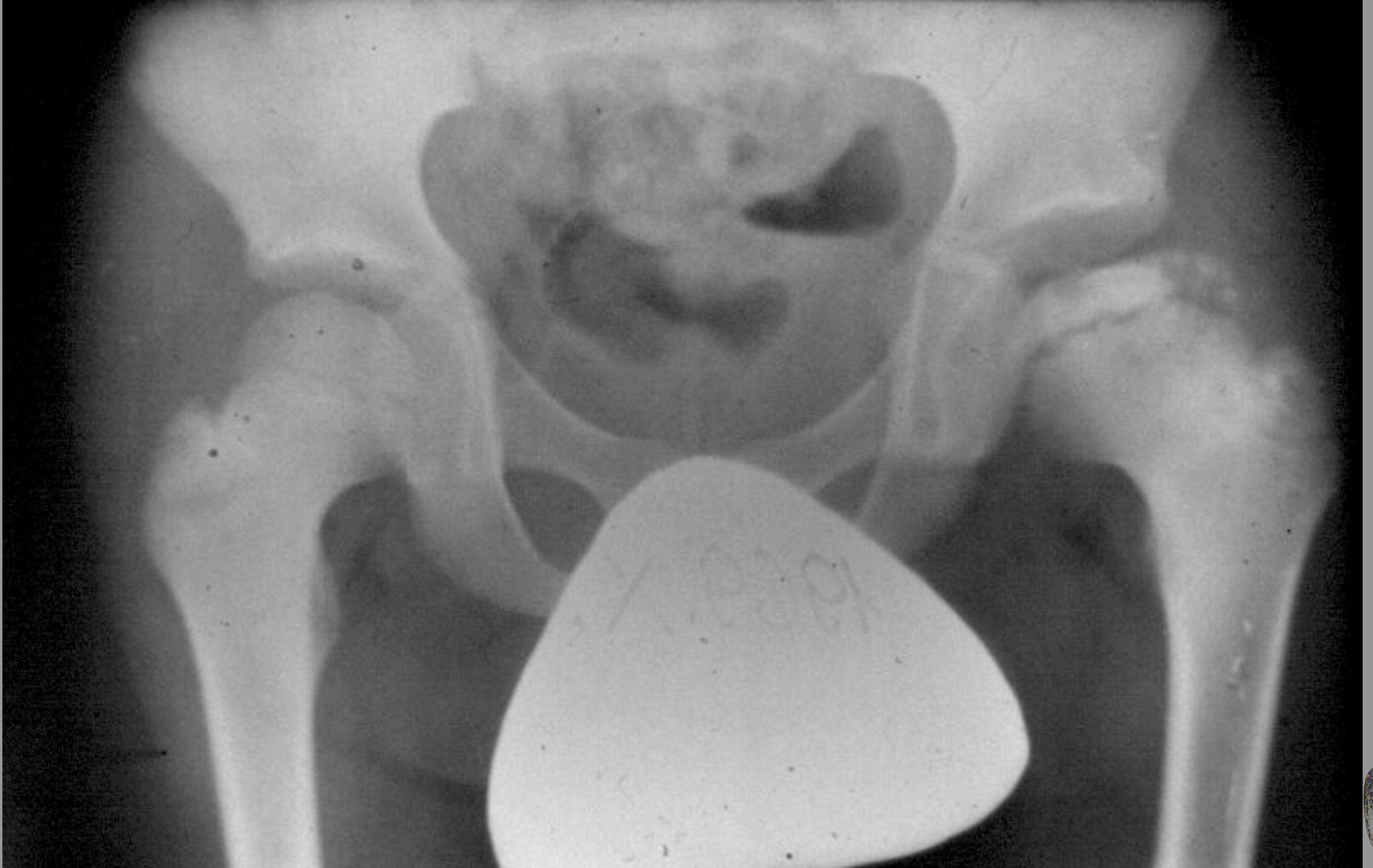

Early stage

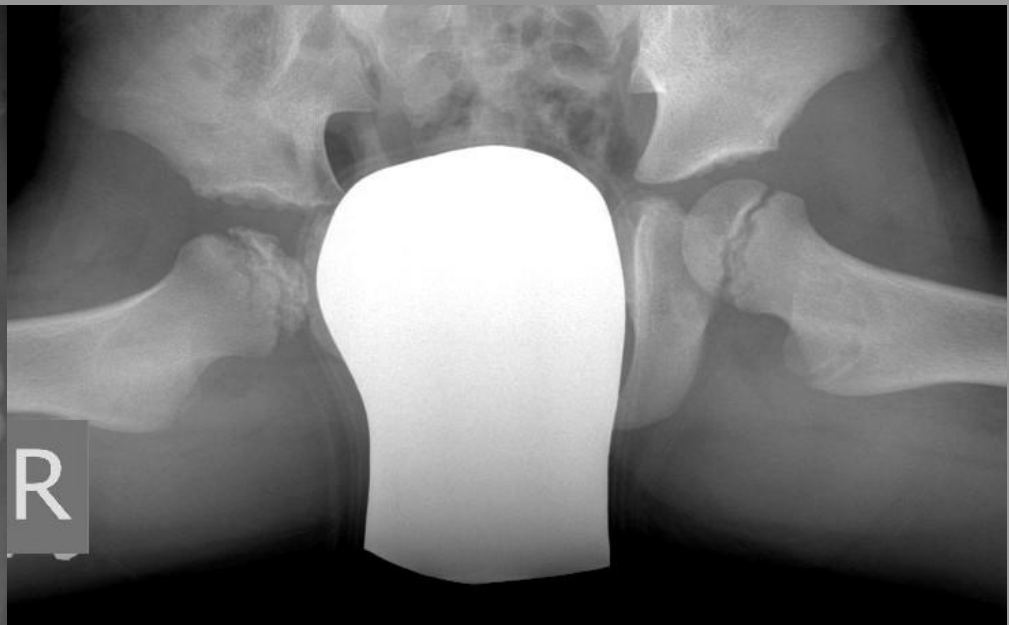
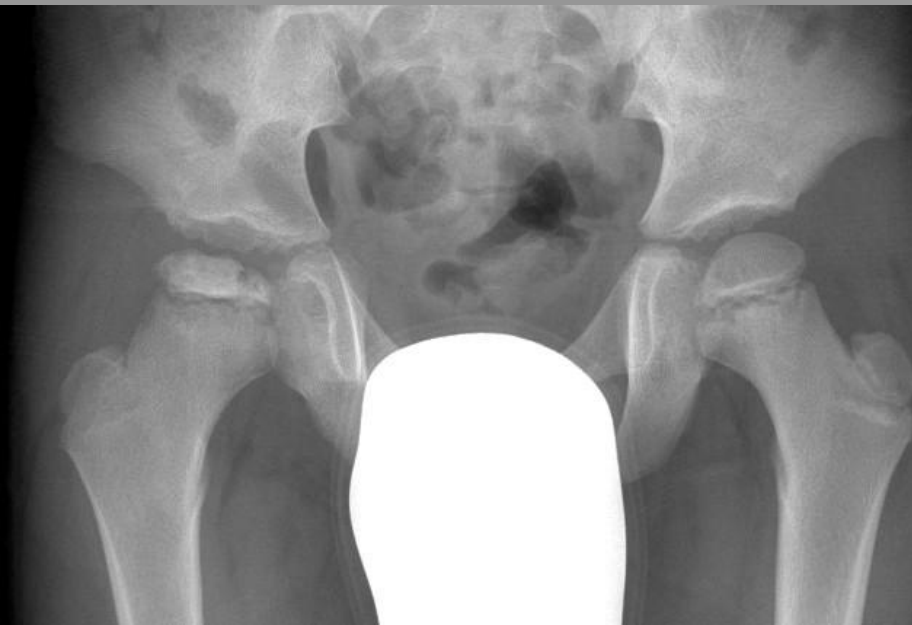- no X-ray sign
- wider joint space medially



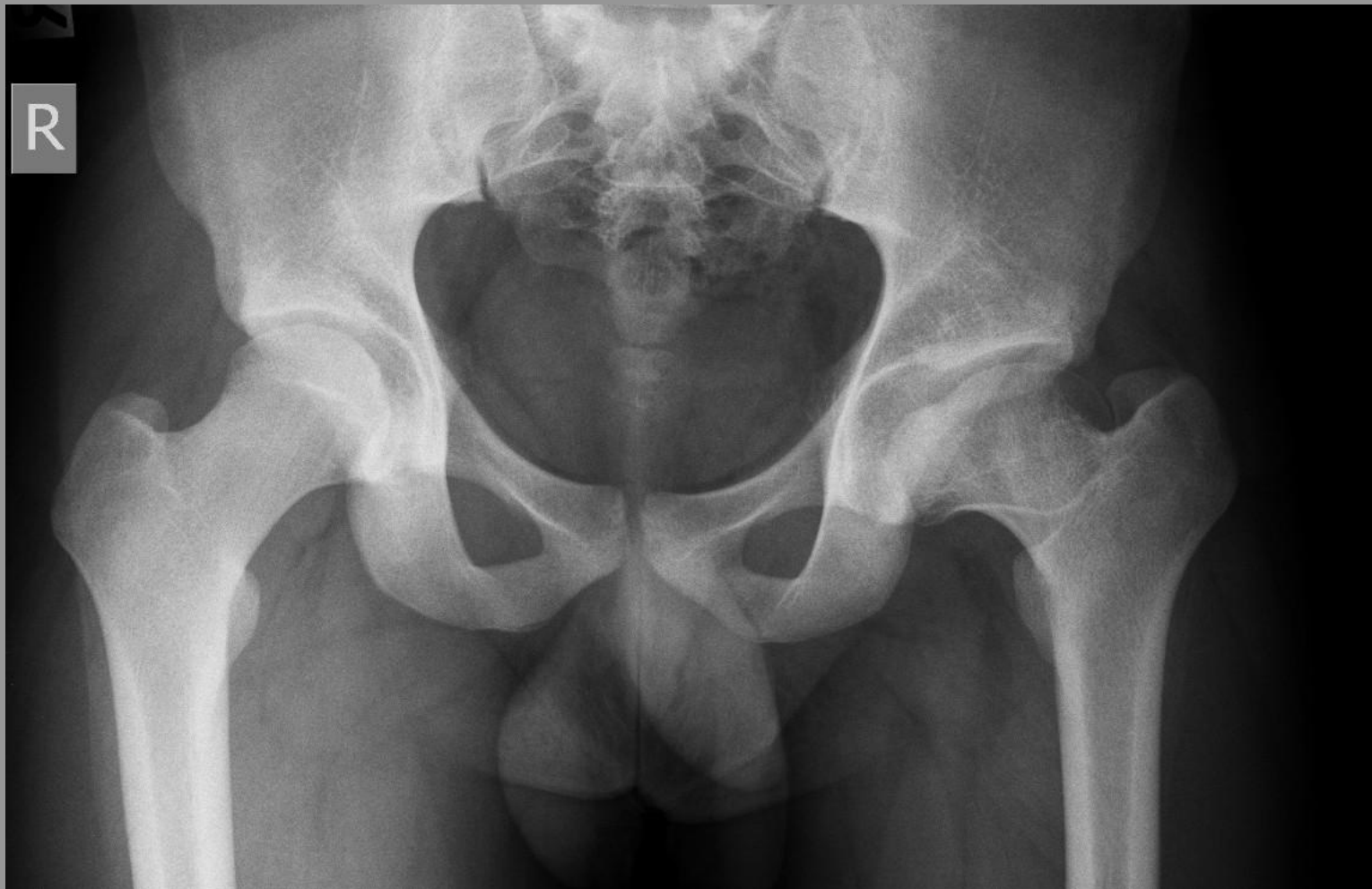Sclerotic stage



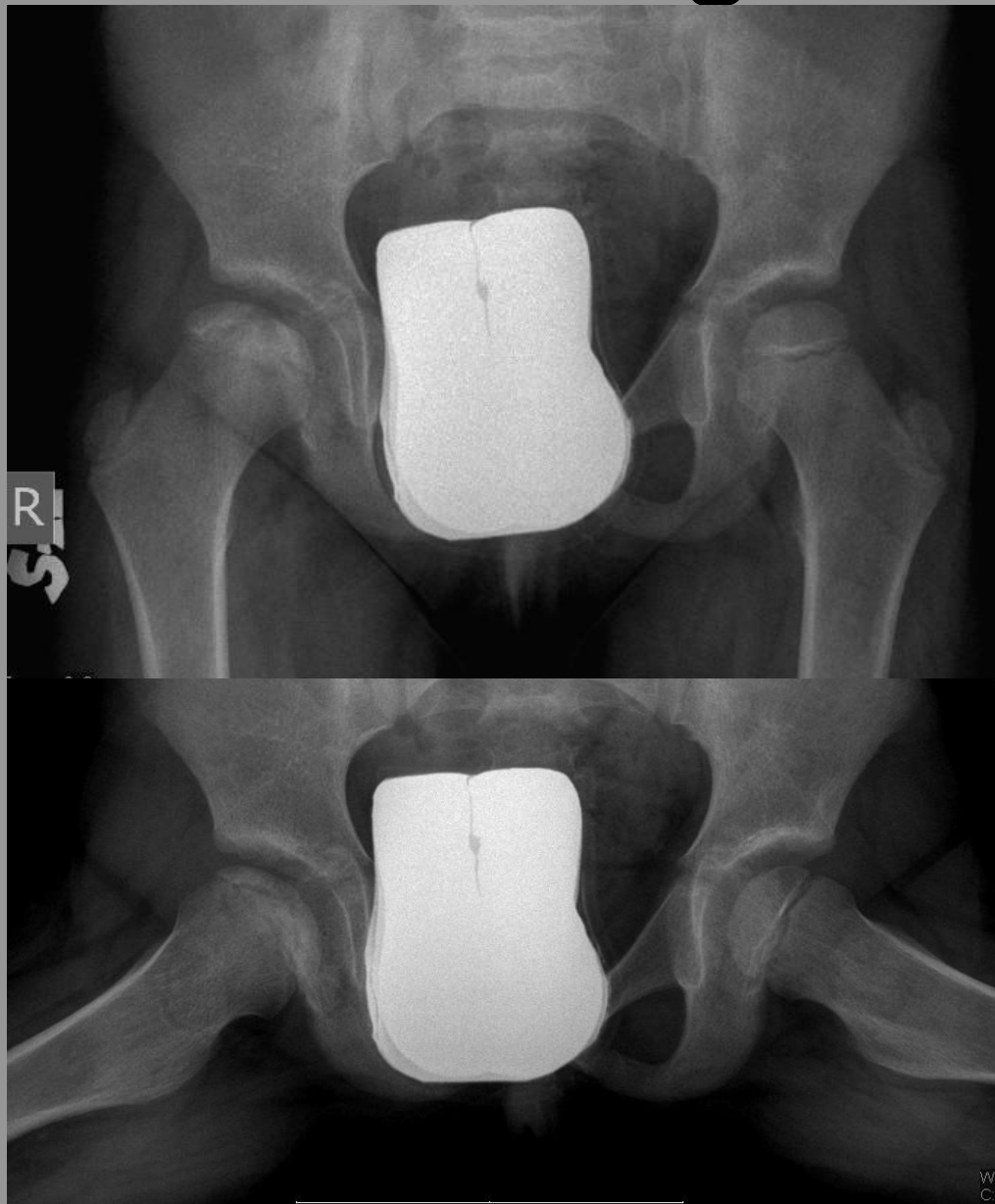
Fragmentation



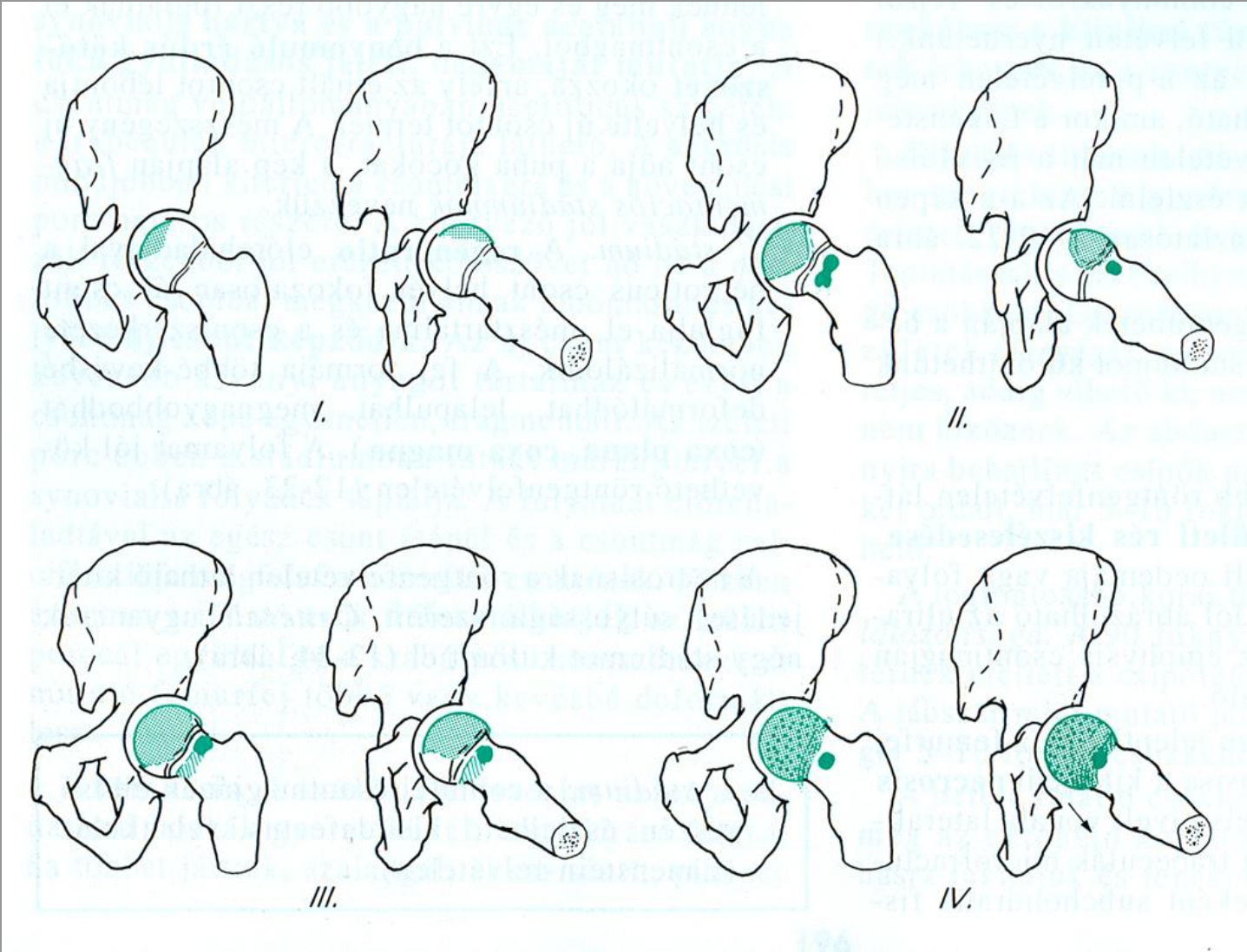
End stage




End stage



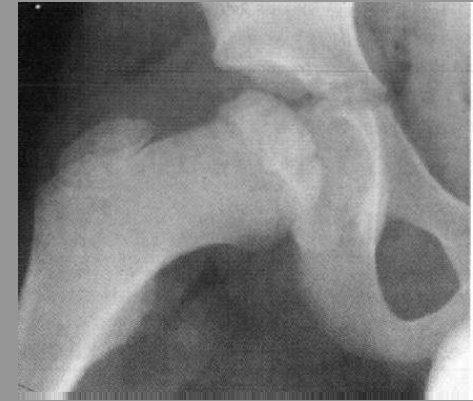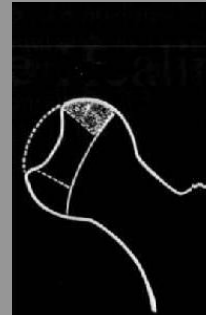Catterall's classification



Herring's lateral pillar classification

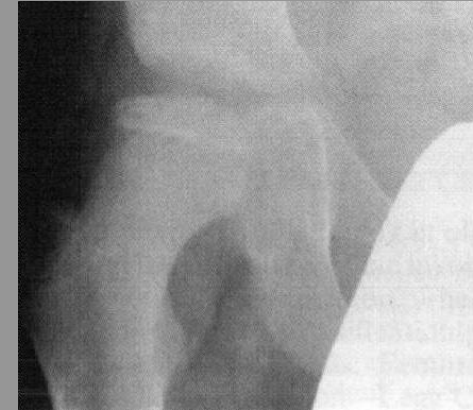
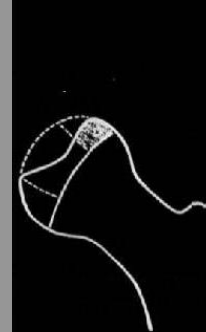
100%



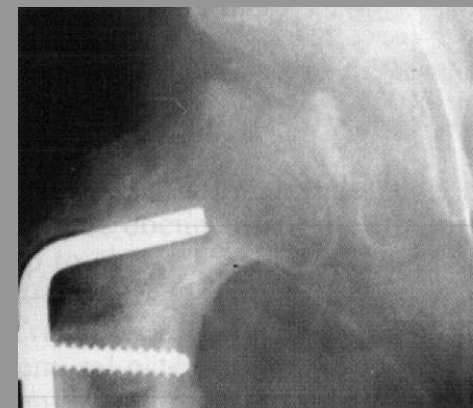
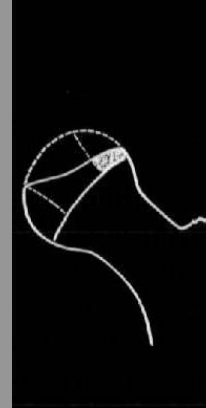
A

>50%

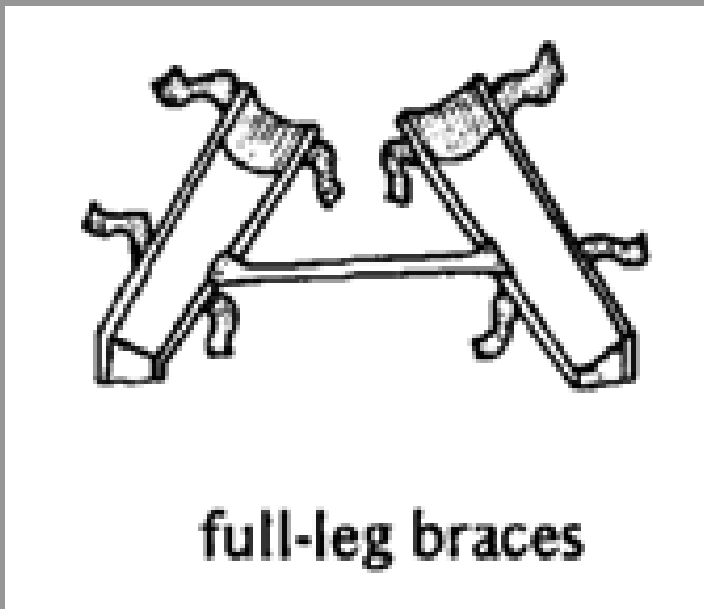
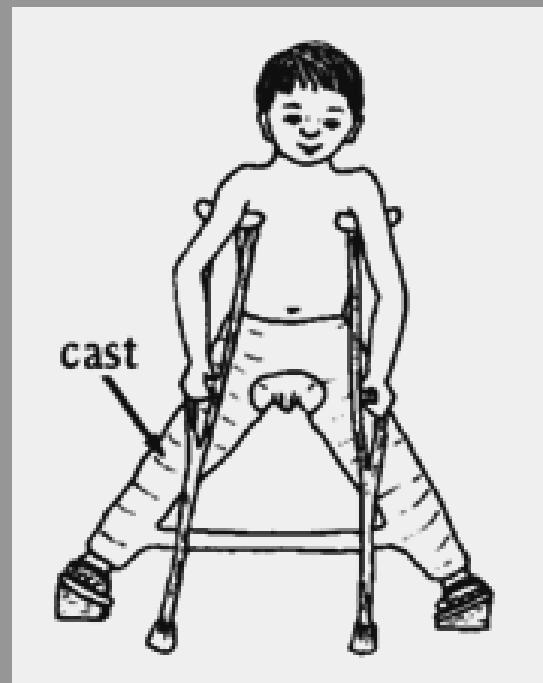
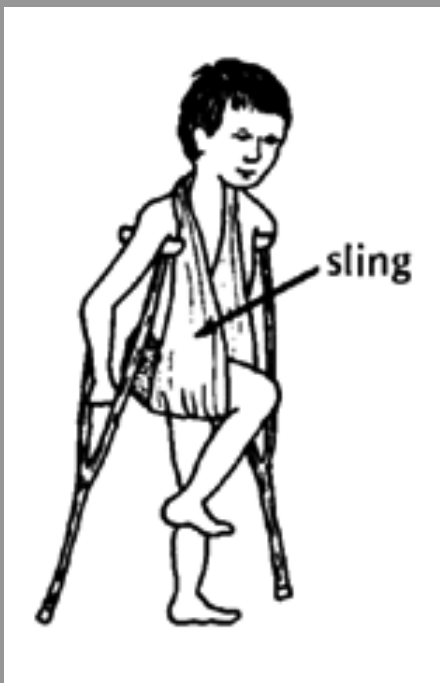

B

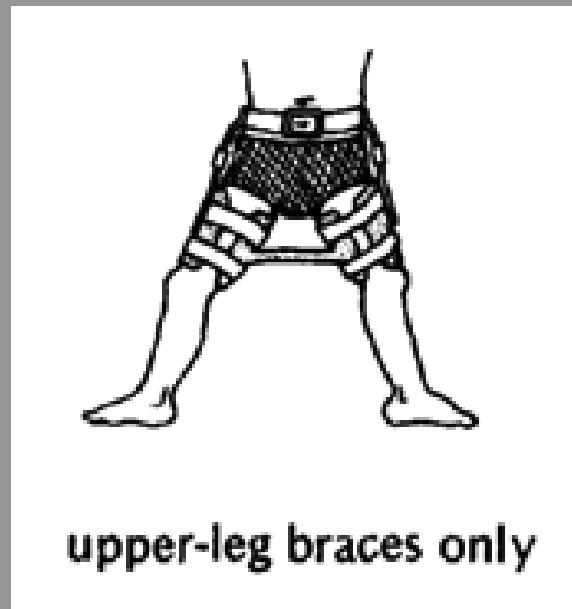<50%



C

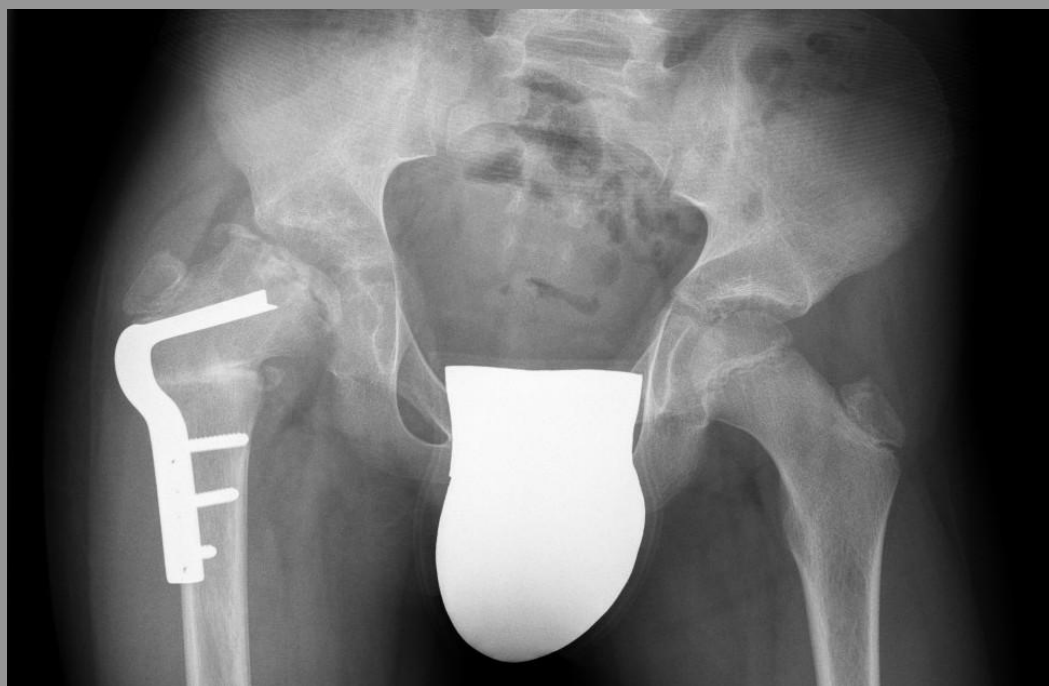
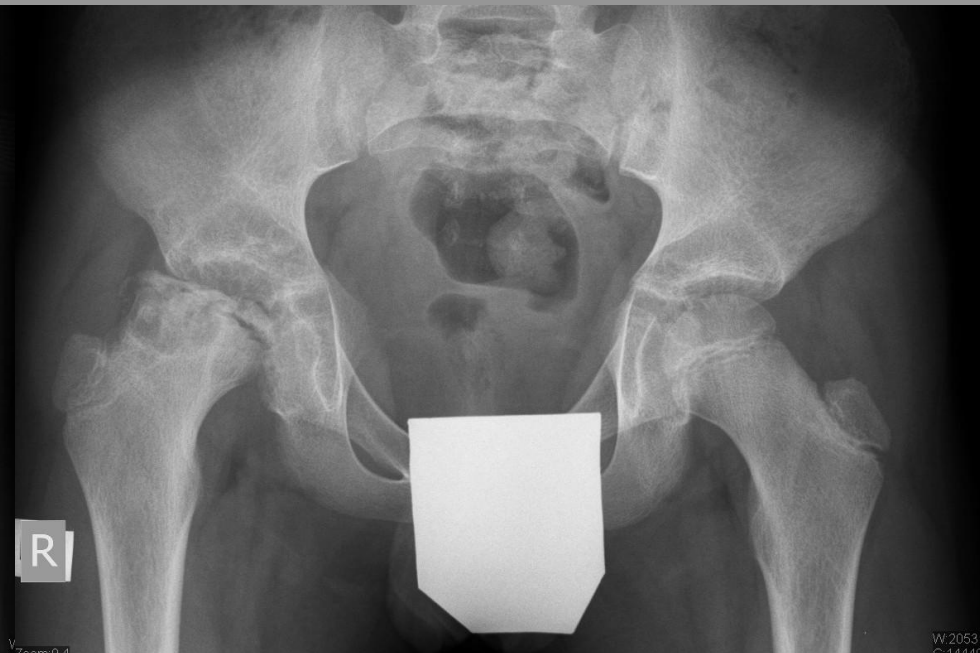
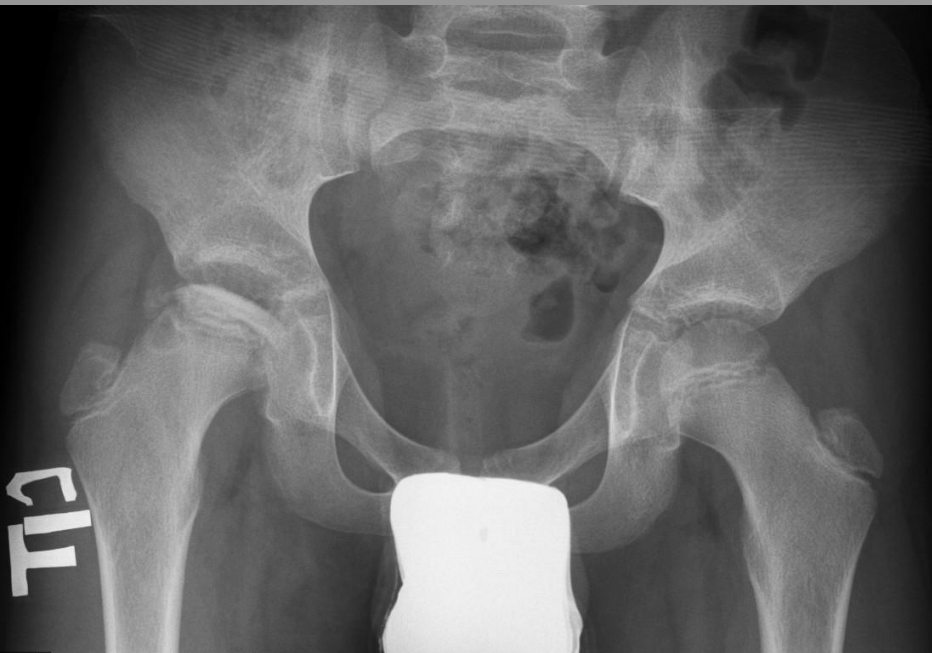
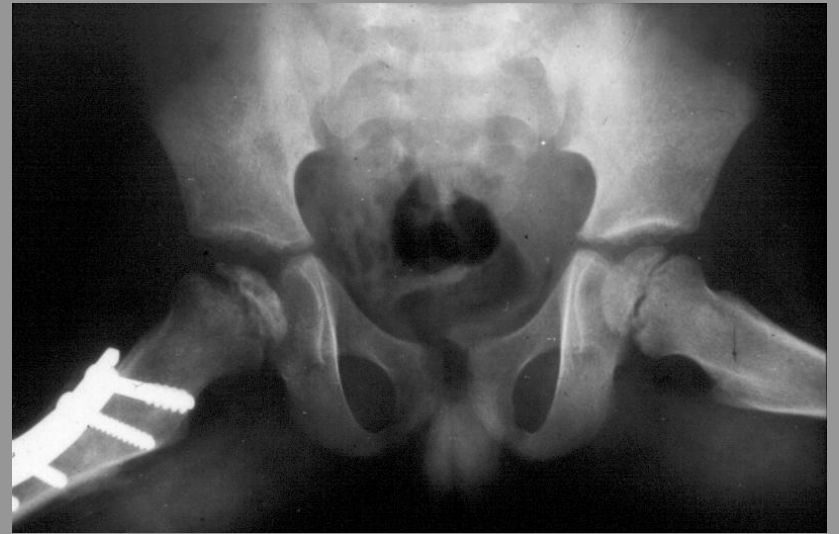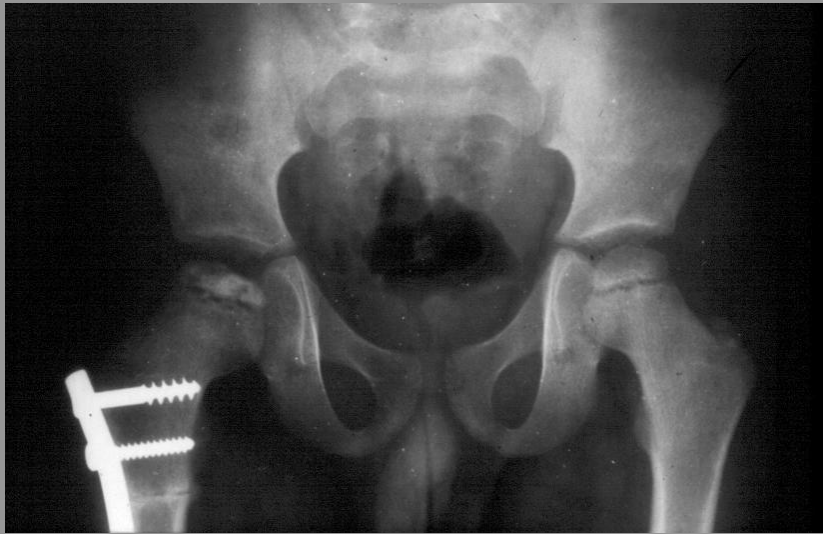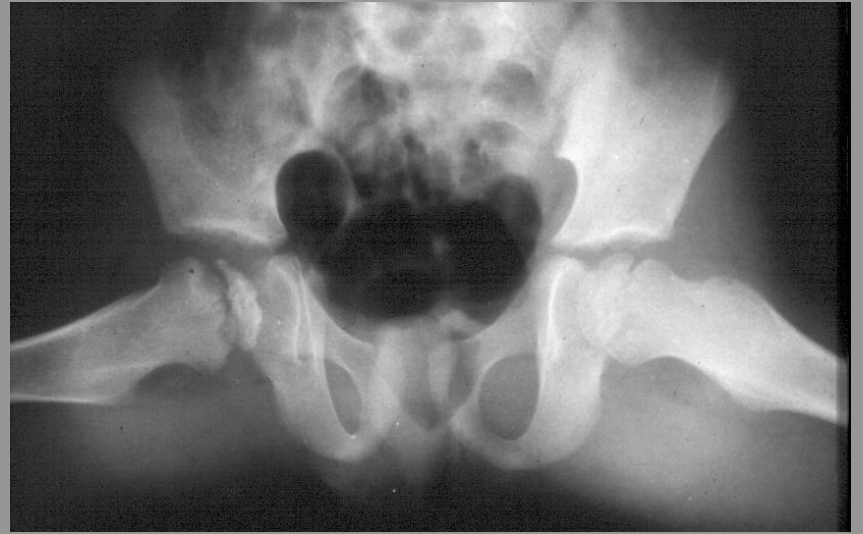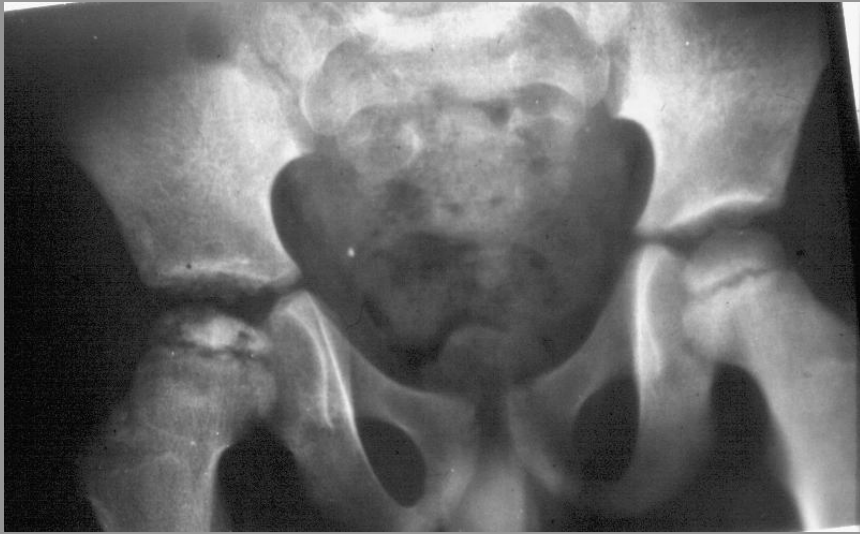full-leg braces



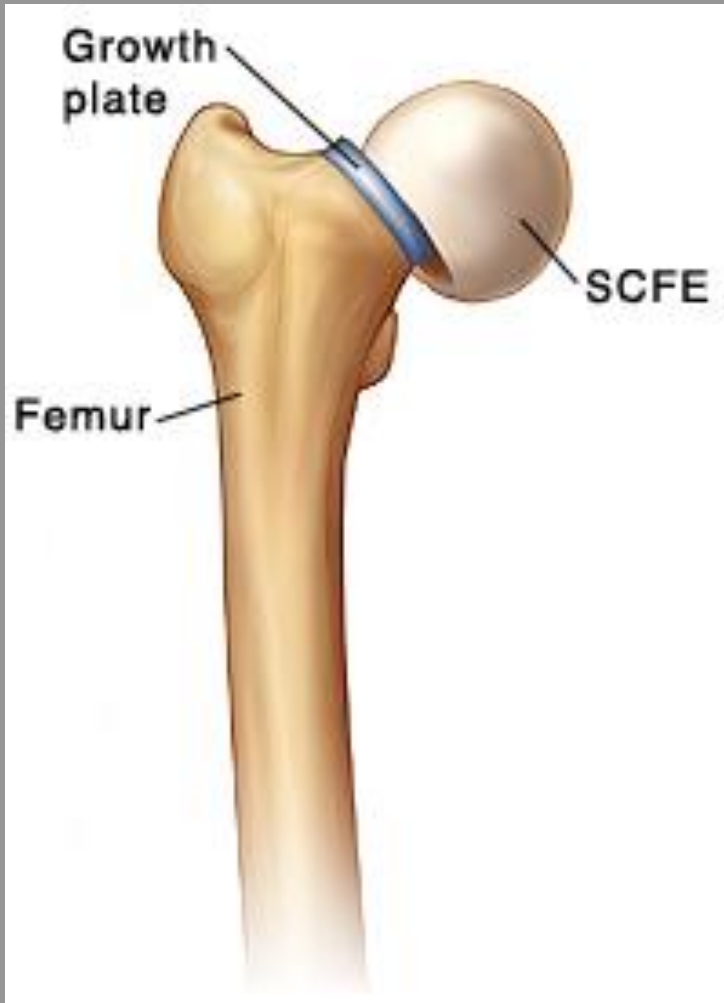
upper-leg braces only







Slipped capital femoral epiphysis



- acute
- chronic
- acute on chronic

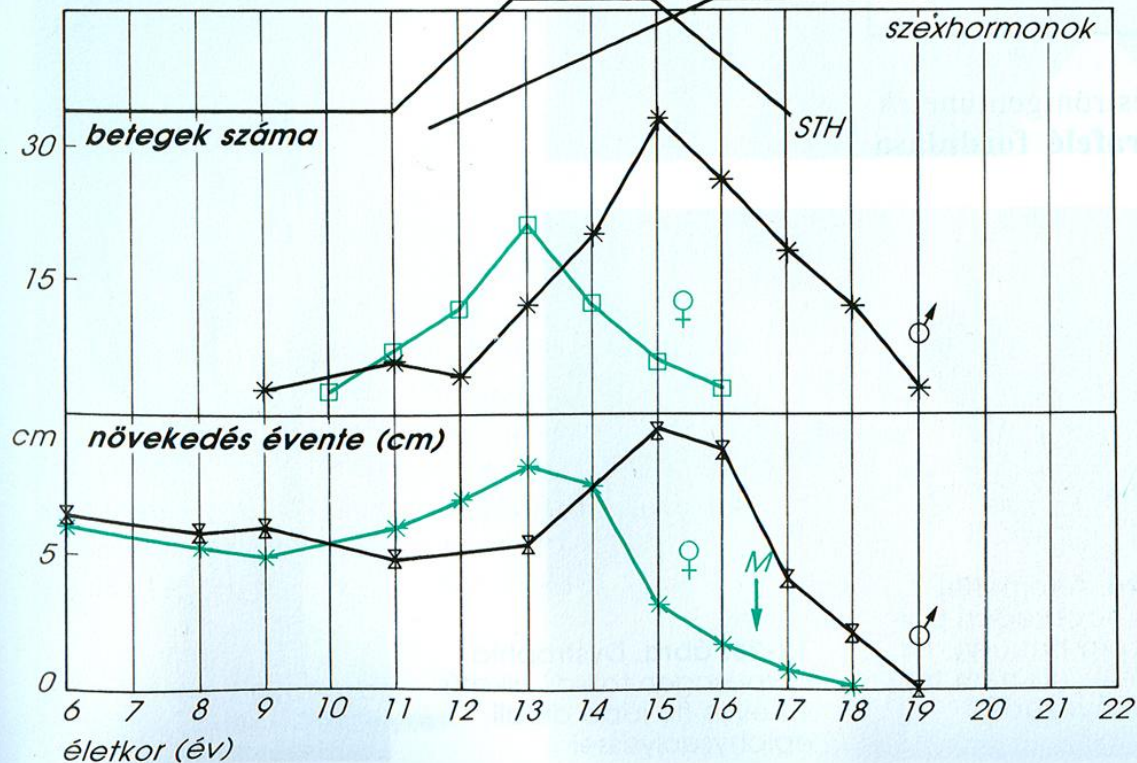
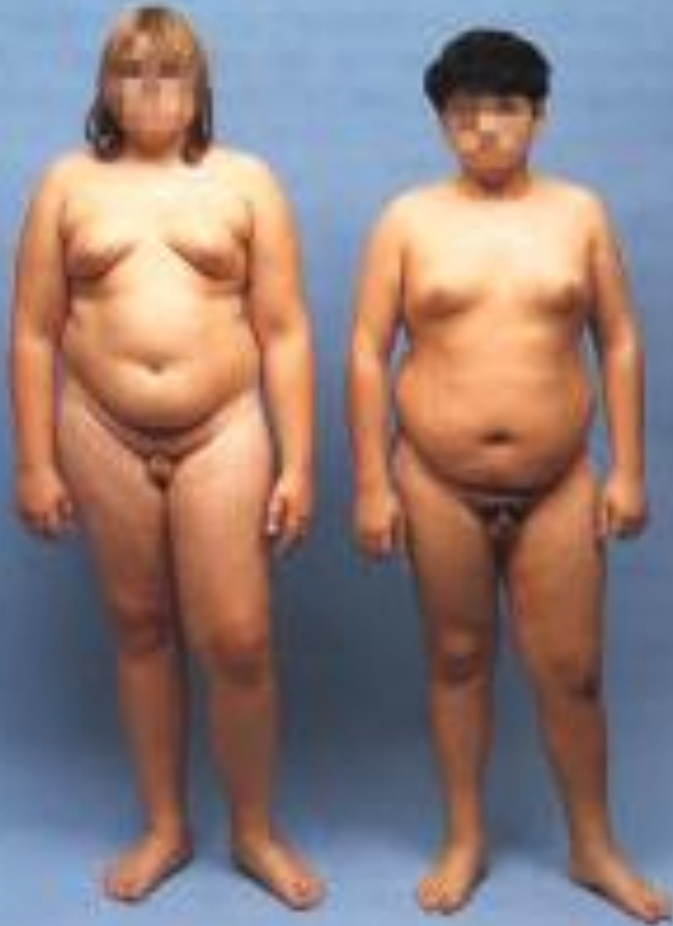

Slipped capital femoral epiphysis

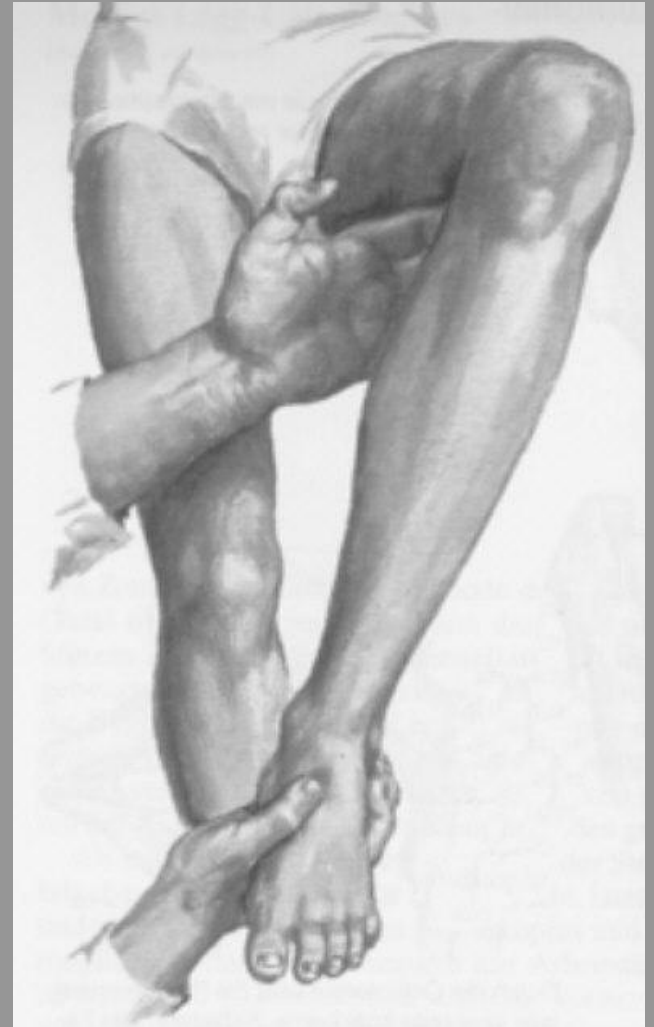
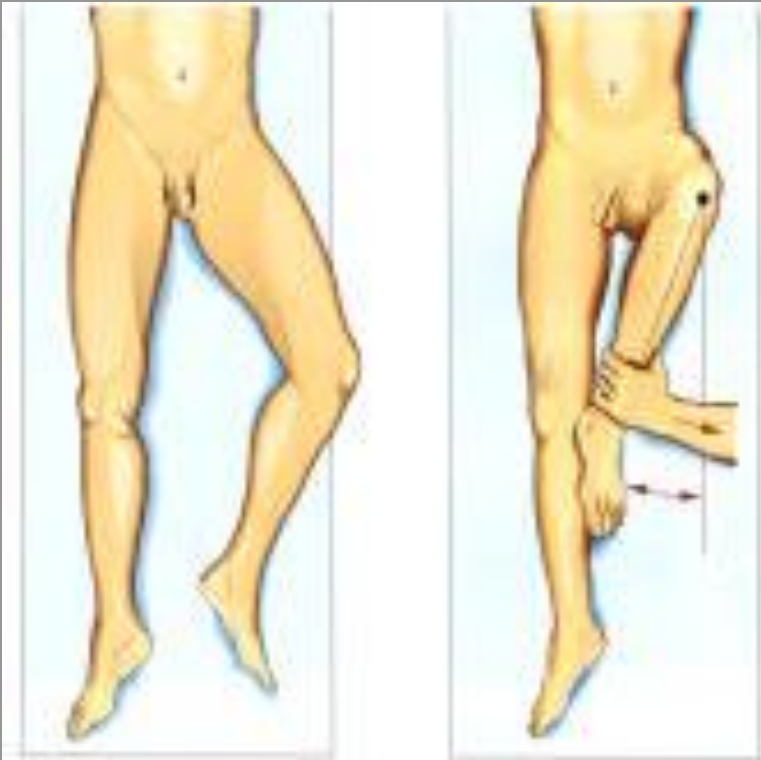- 10-15 years of age
- male : female = 2:1
- 75% chronic
- knee/thigh/hip pain!

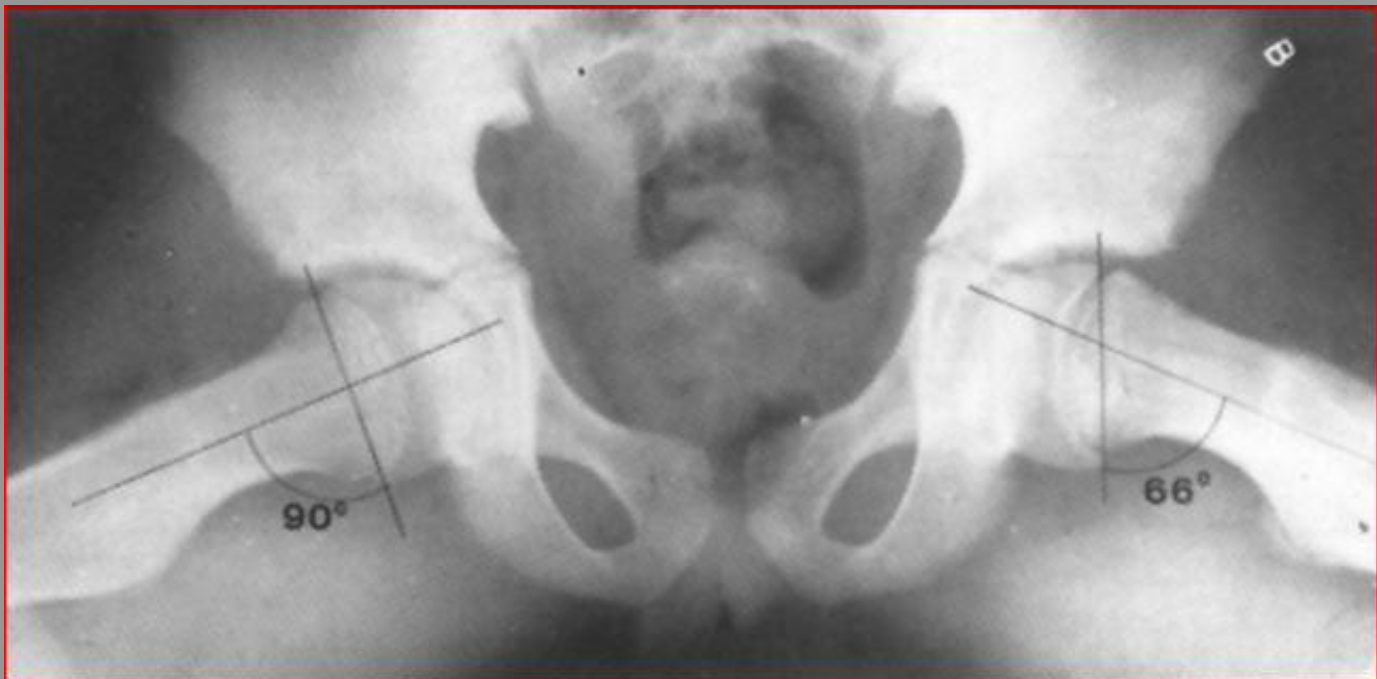
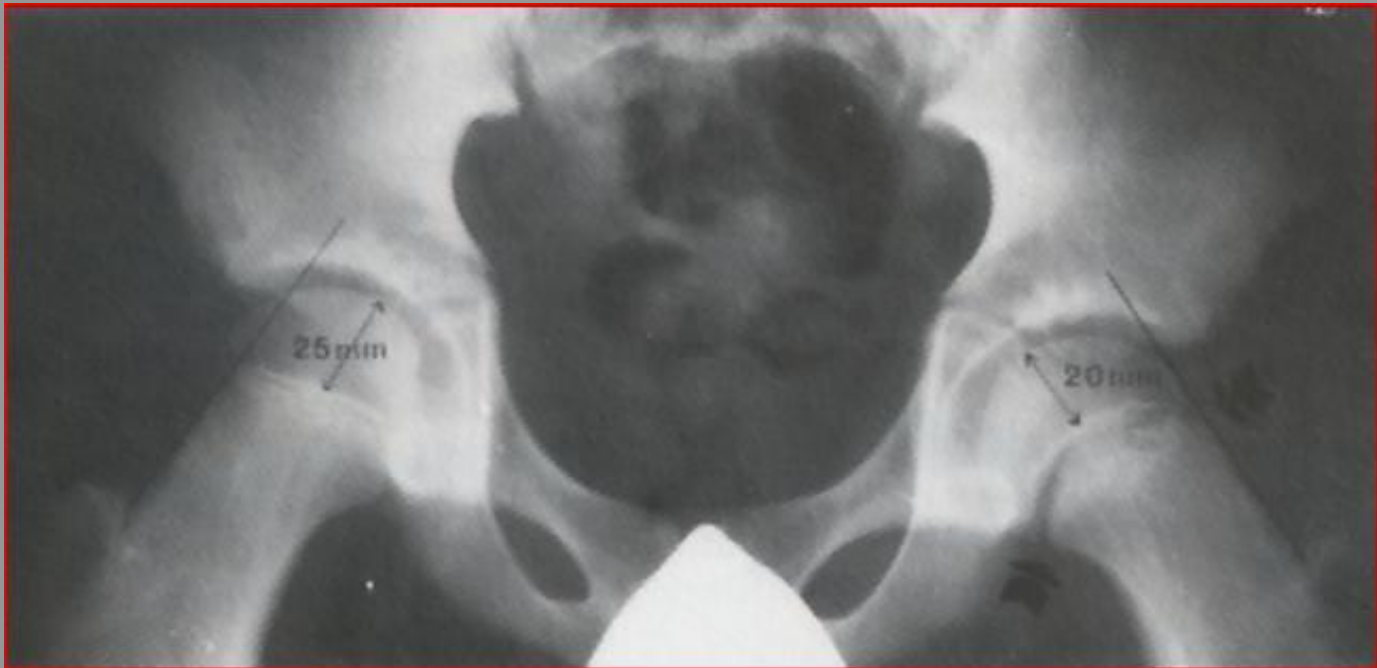
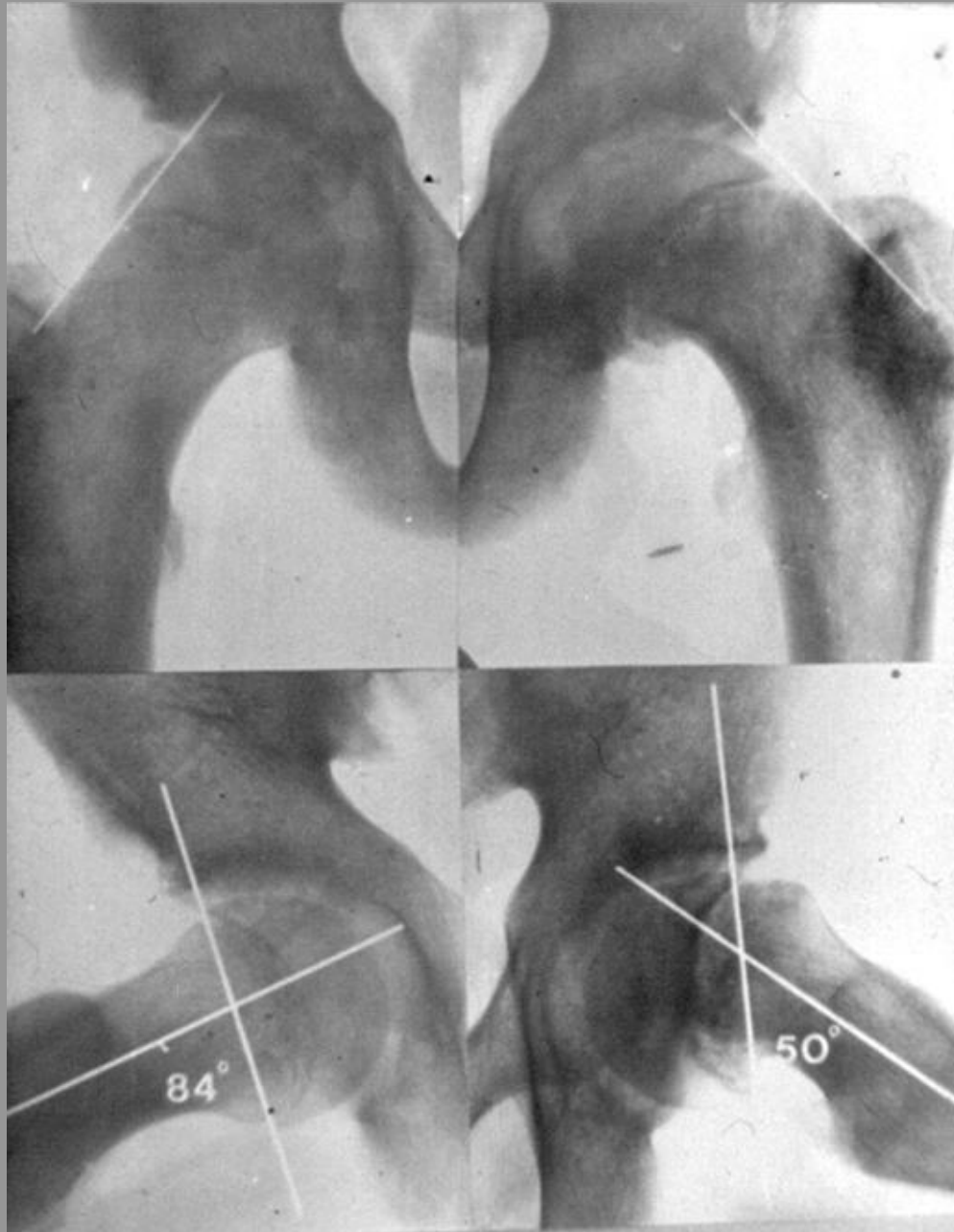
Slipped capital femoral epiphysis



Drehmann's sign

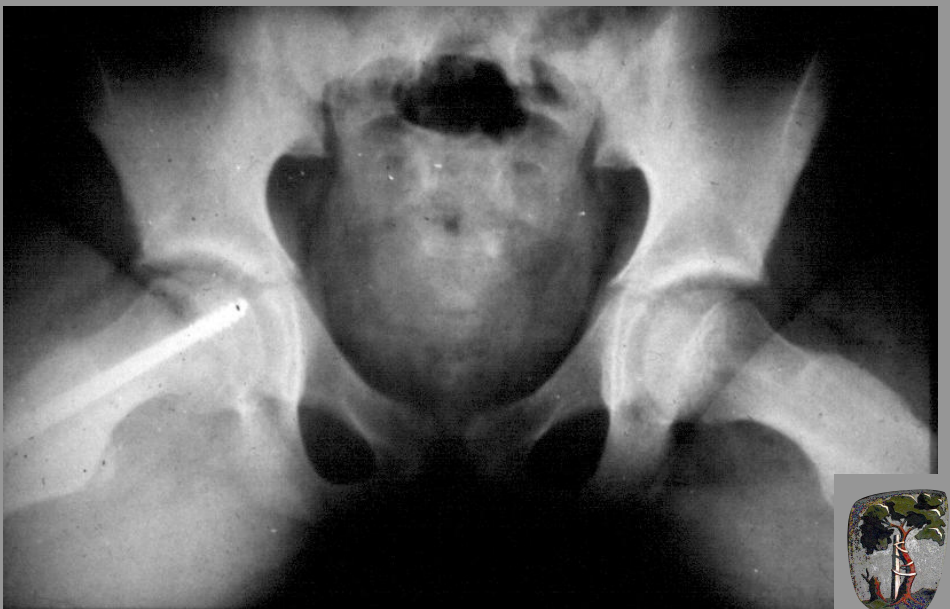
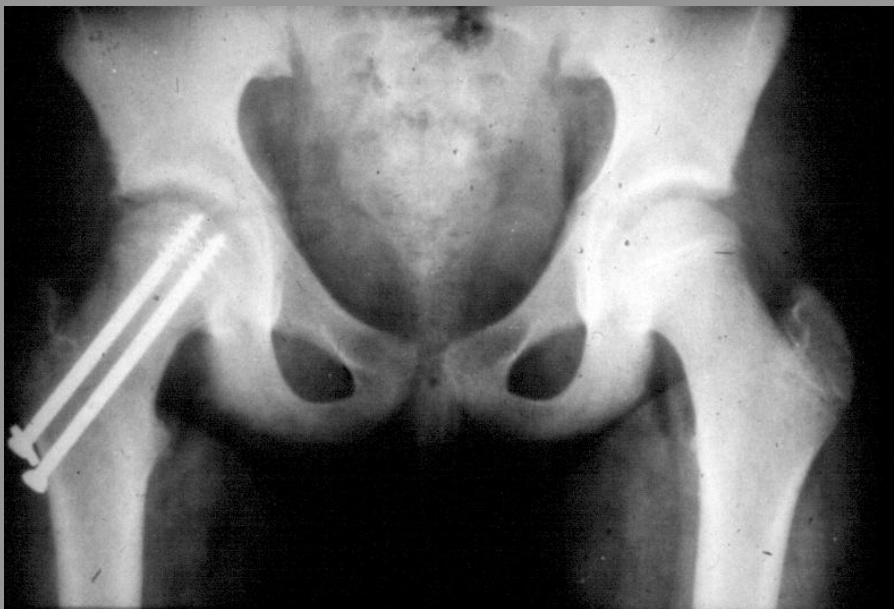
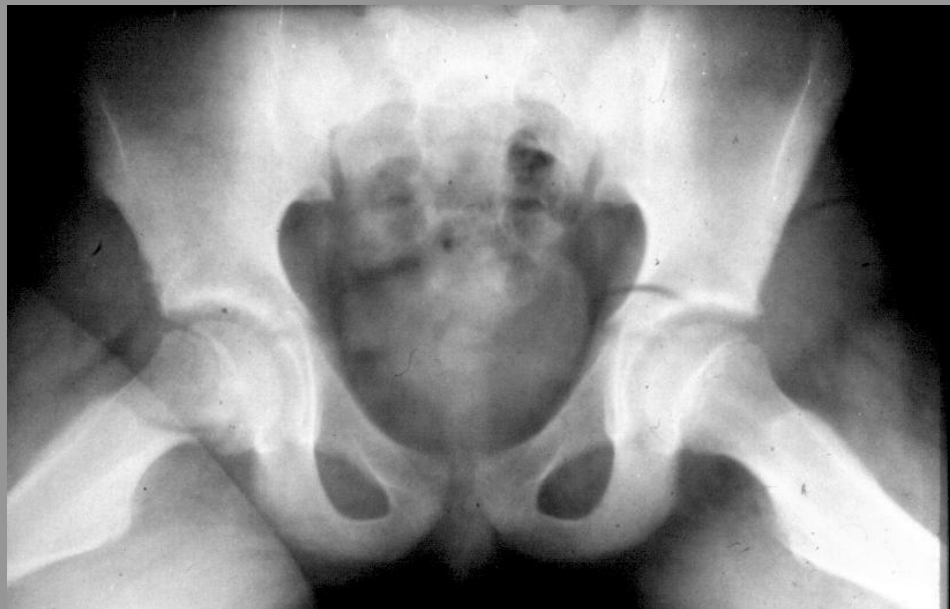
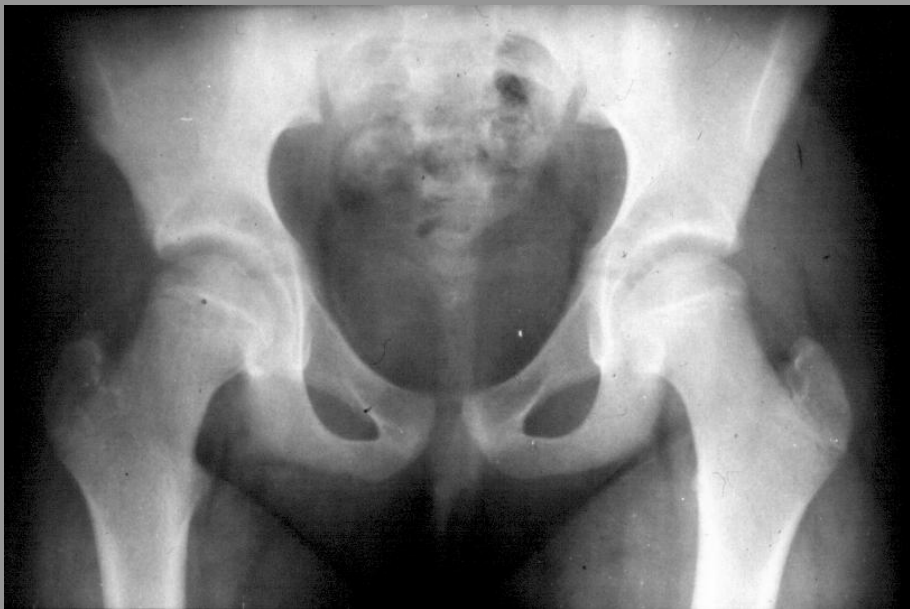


Blood Supply to Head and Neck of Femur

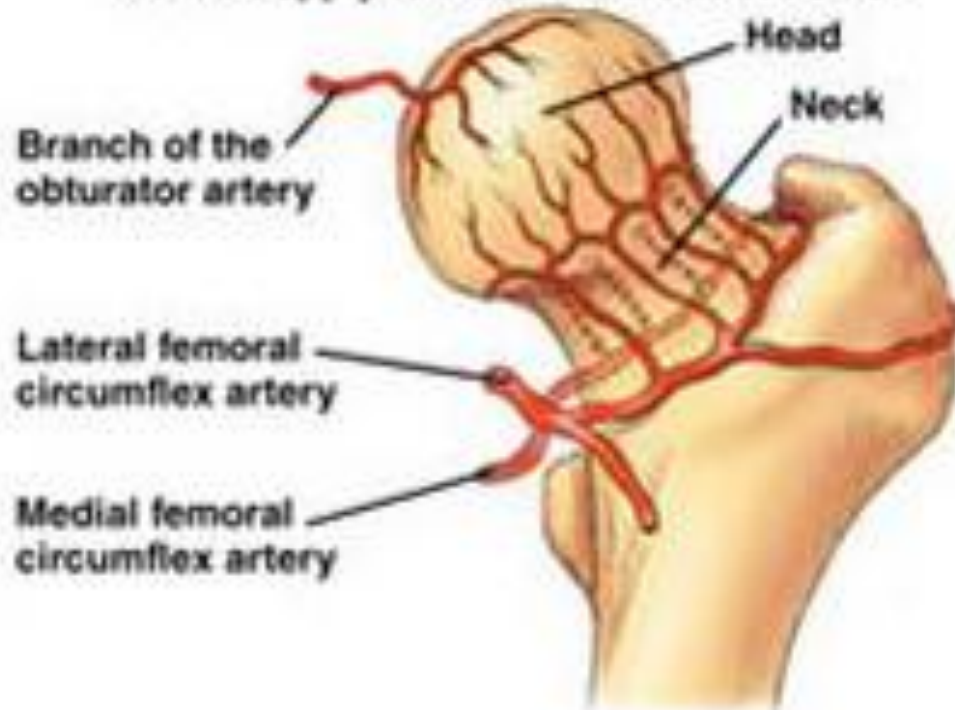



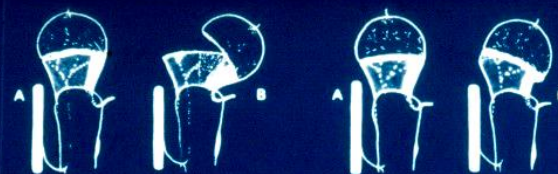
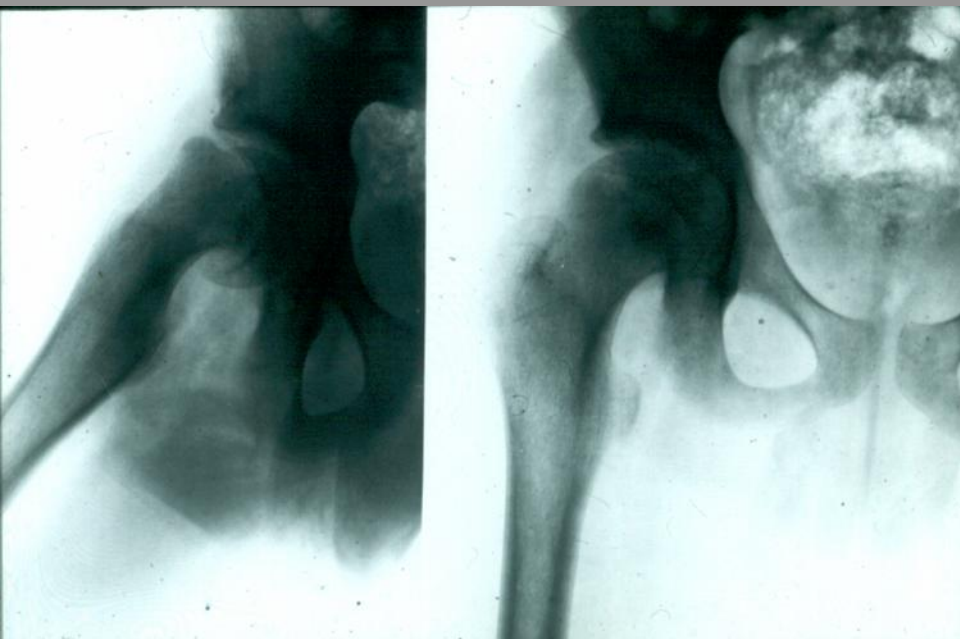

Fig. 1

Fig. 2


Figure 1—A. Lateral diagram of normal femoral head showing the vascular arrangement. B. Acute traumatic displacement in previously normal hip. Figure 2—A. Normal femoral head. B. Early chronic slip (Type 1).

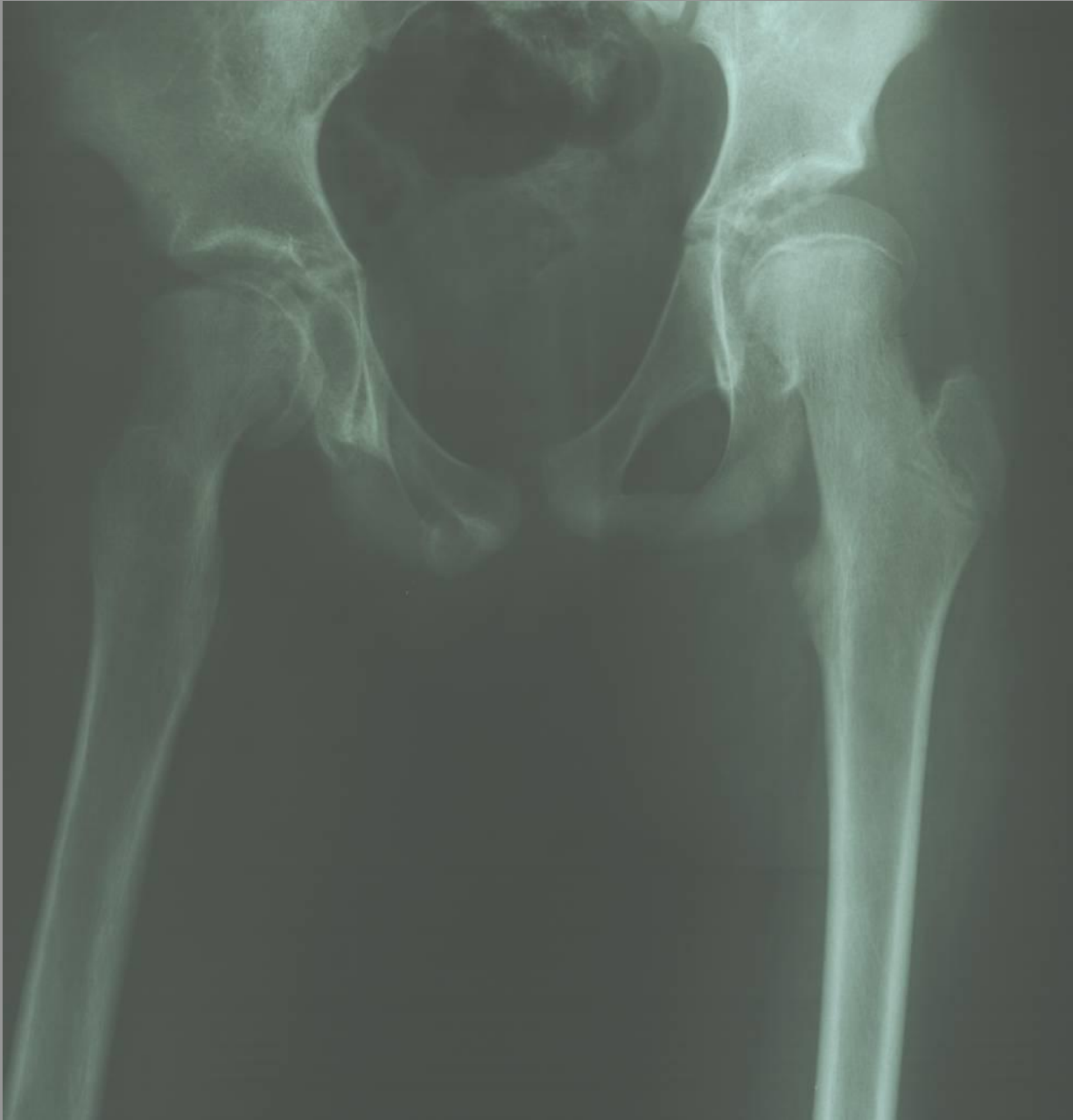

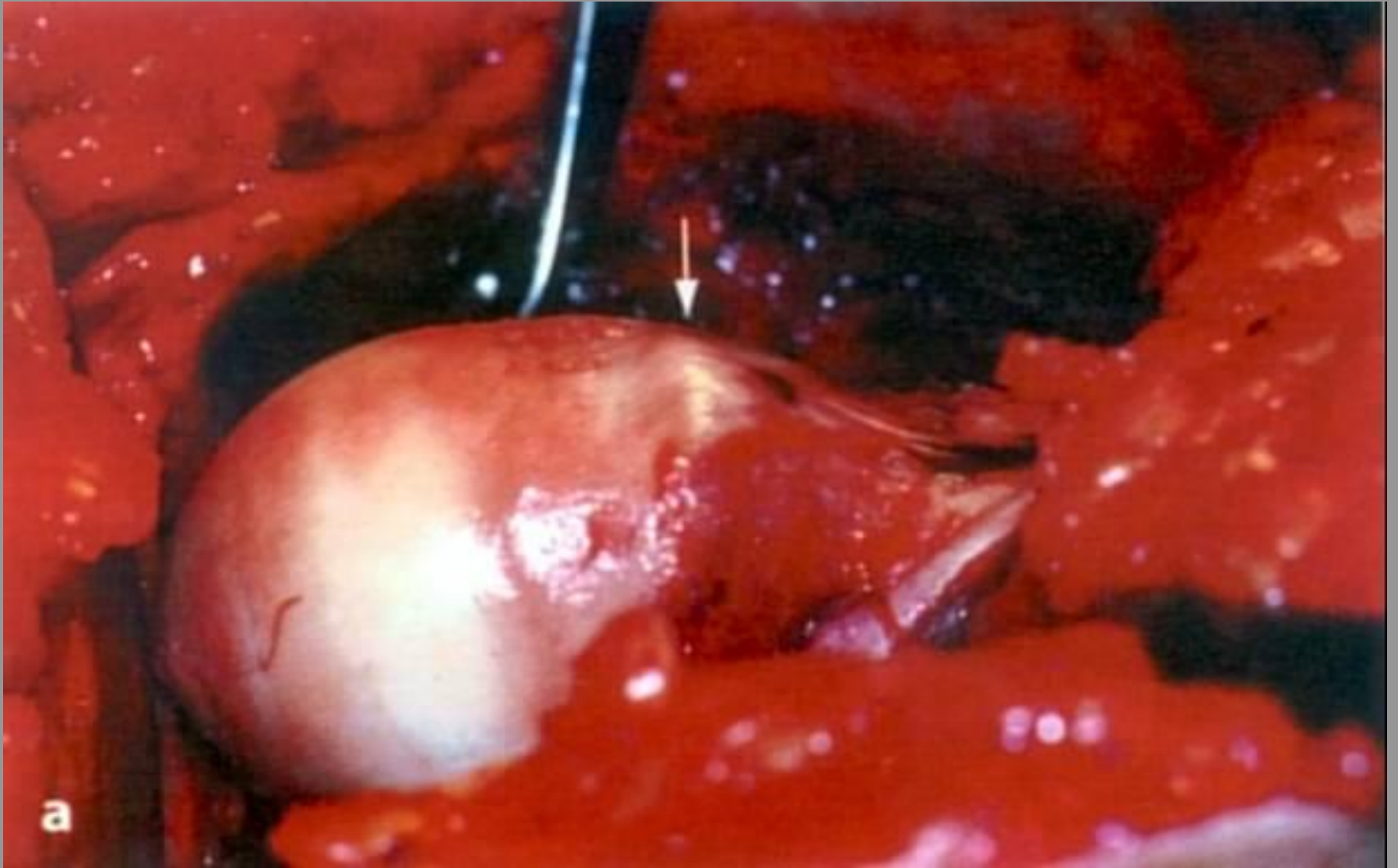
Fig. 3

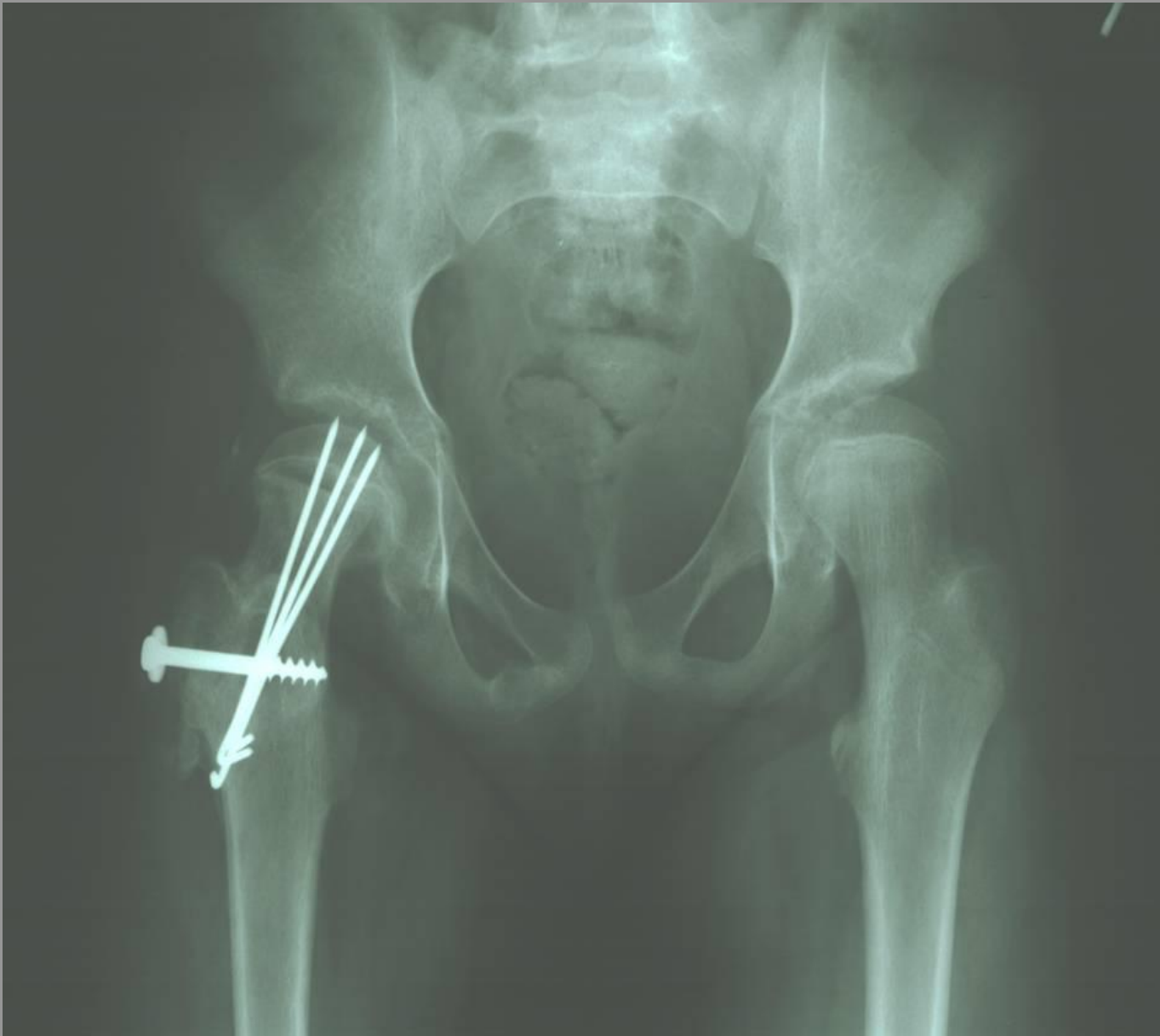Fig. 4

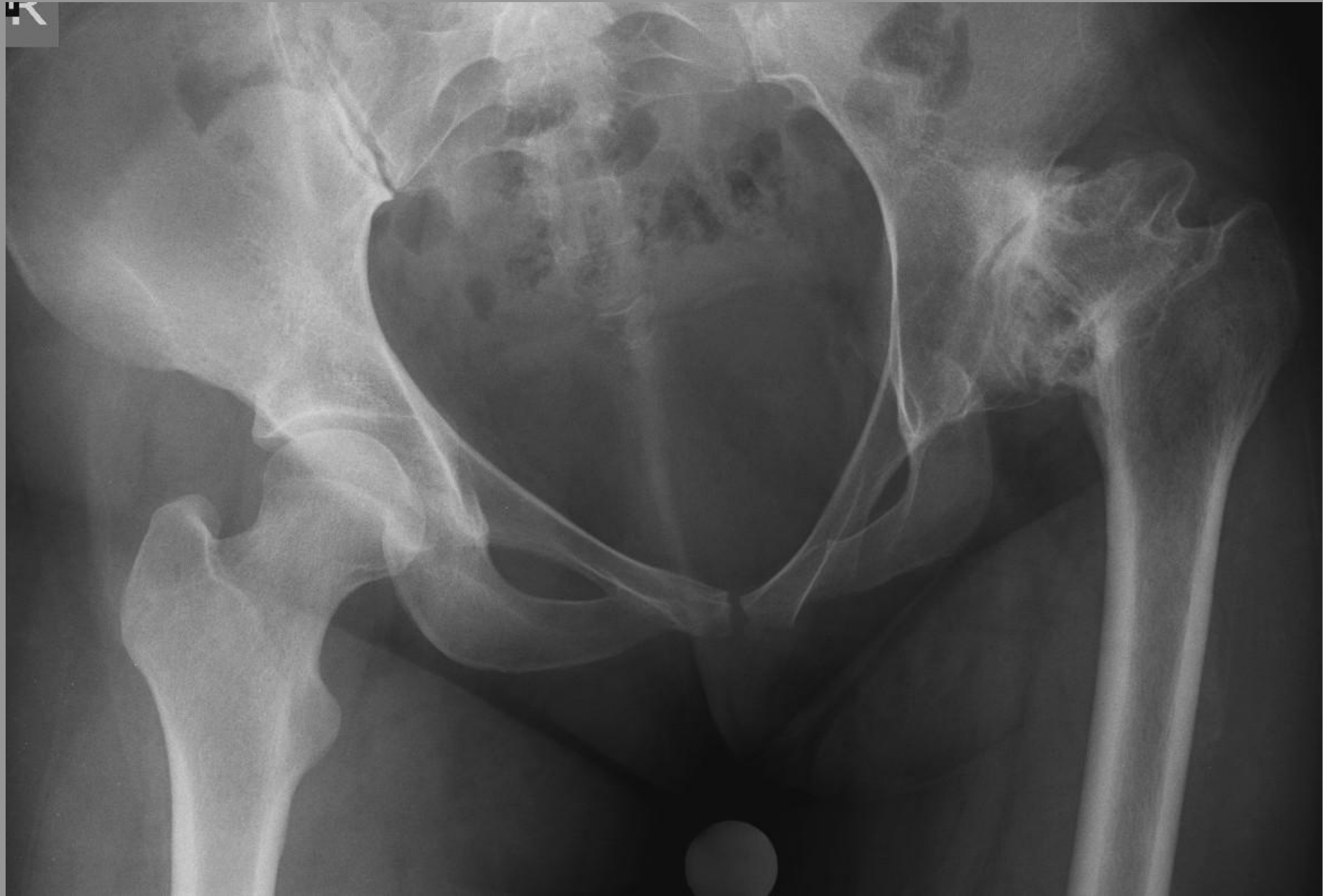
Figure 3—A. Early chronic slip. B. Acute-on-chronic slip (Type 2). Figure 4—A. Late chronic slip with plate open (Type 3). B. Late chronic slip with plate closed (Type 4).





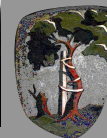
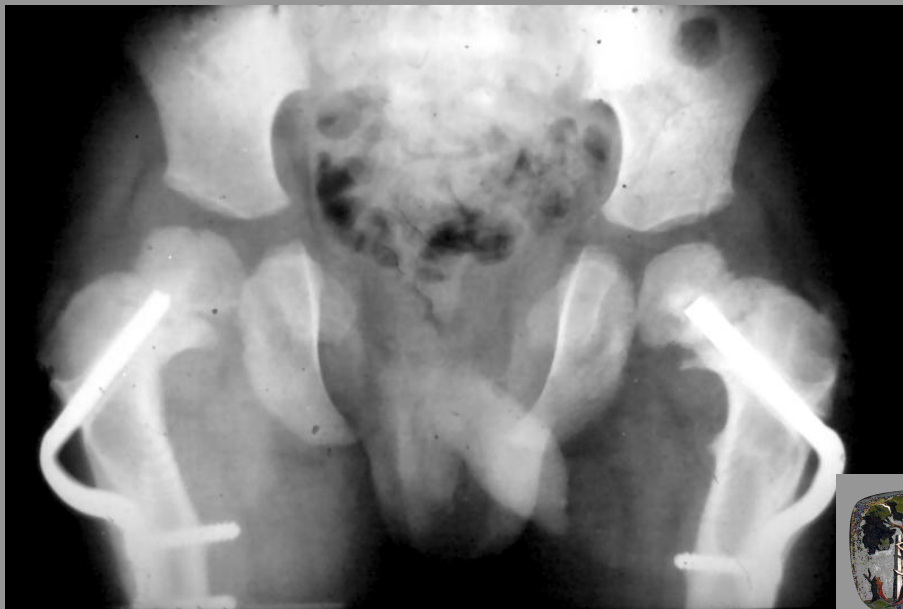
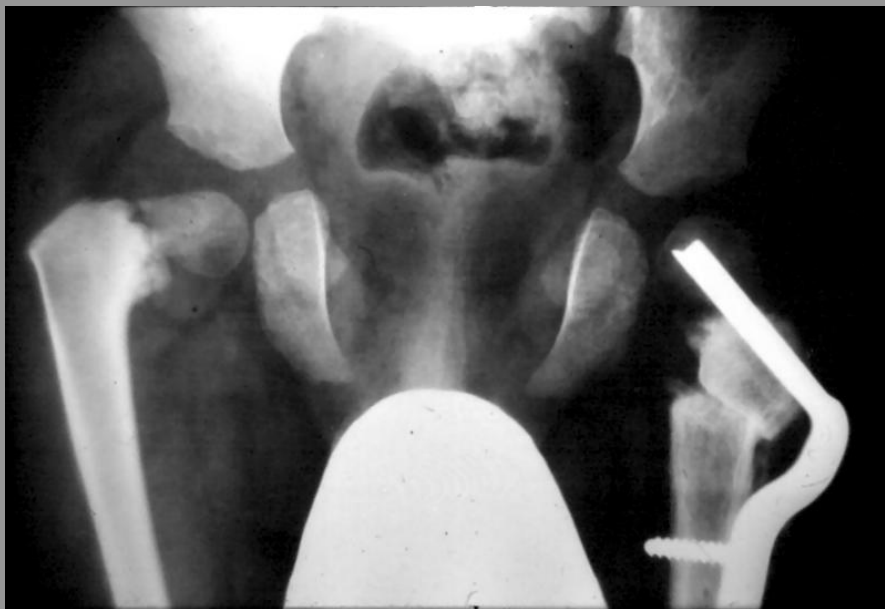
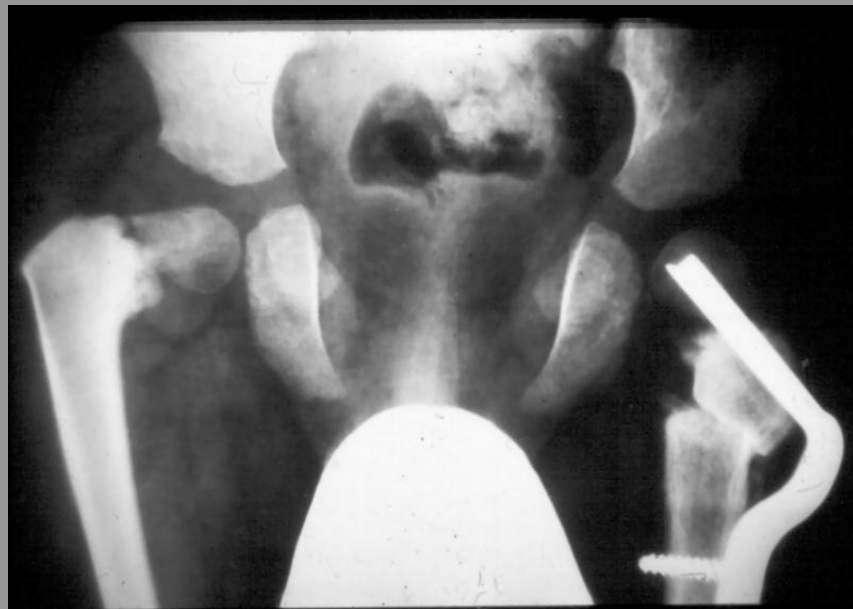
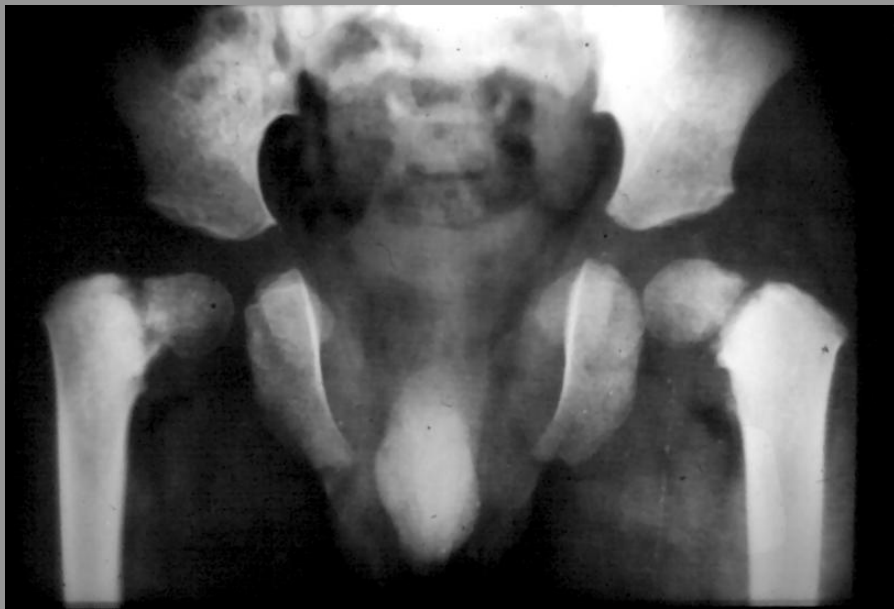


Coxa vara infantum (congenita)

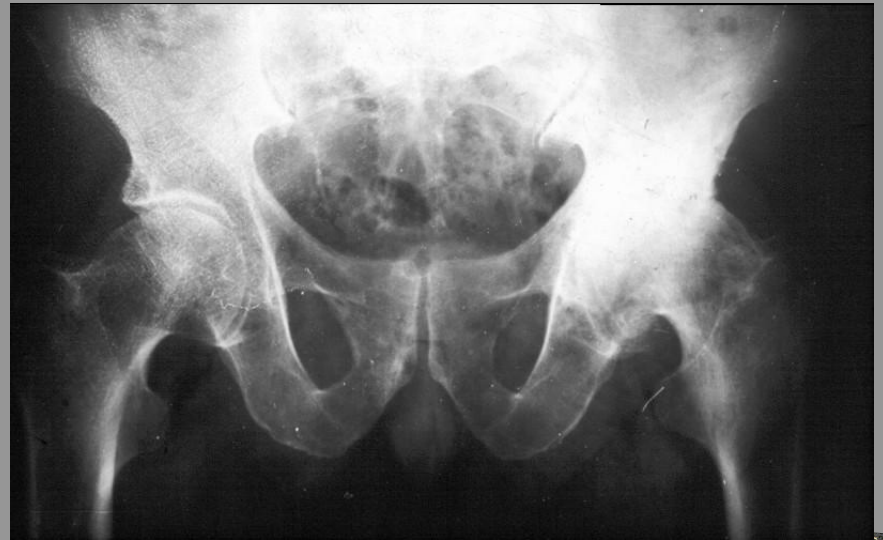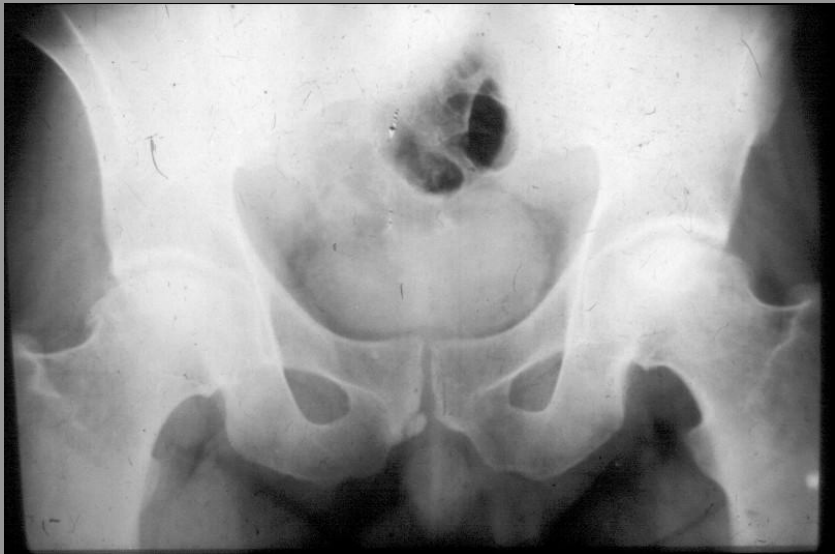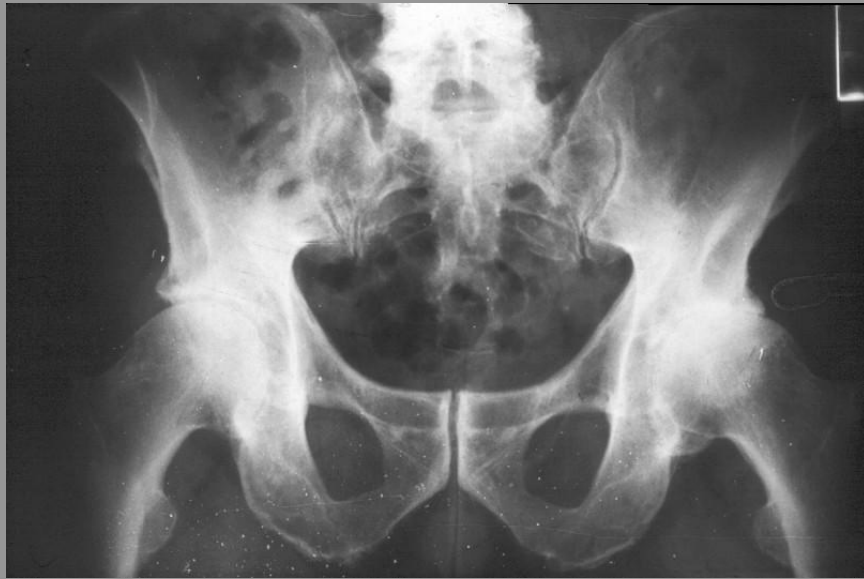- Decreased collo-diaphyseal angle
- Abbreviation of the leg
- Congenital but recognised only at the age of 3-4 years of age
- Rare
- Progressive

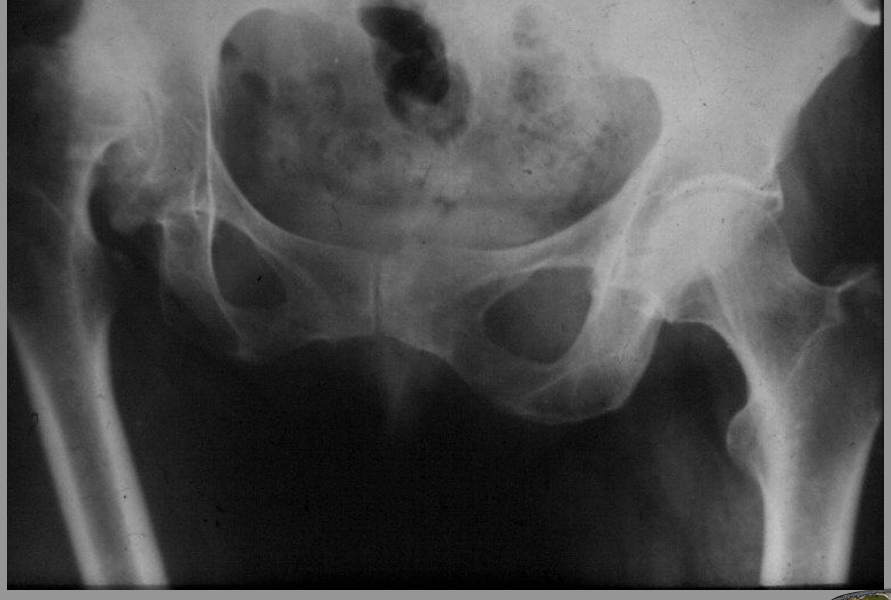
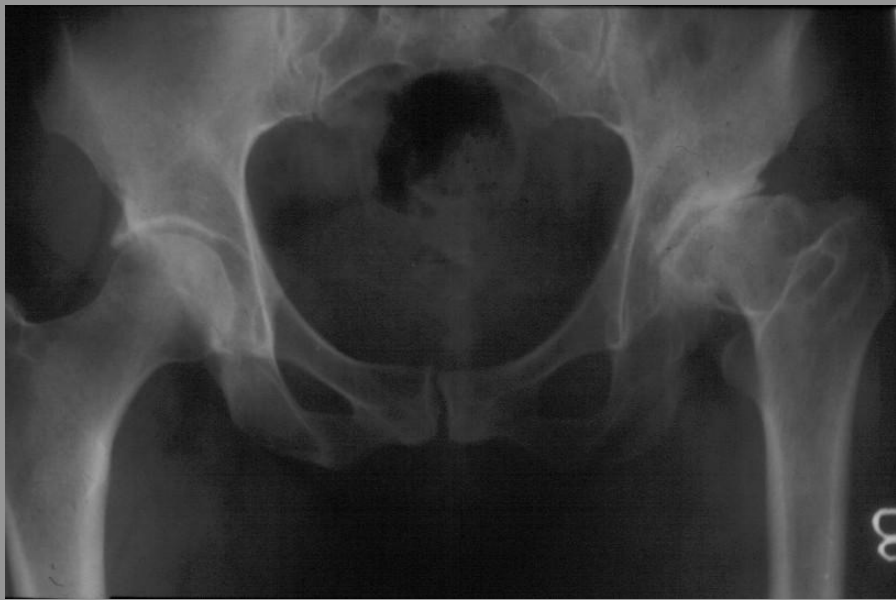
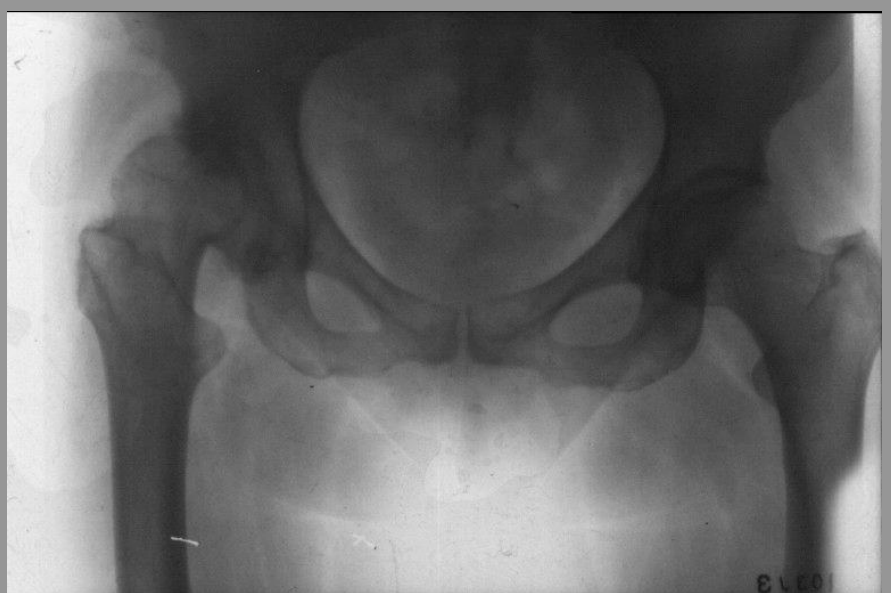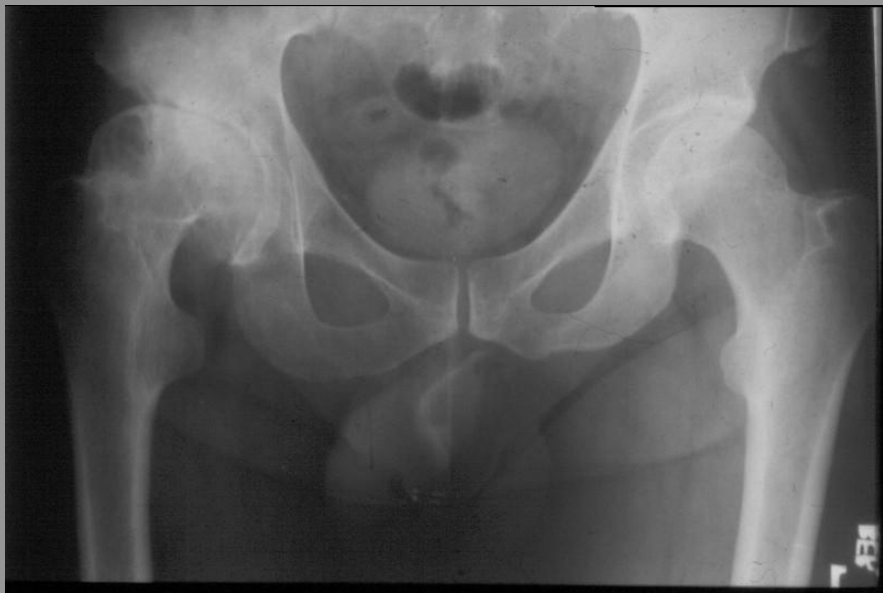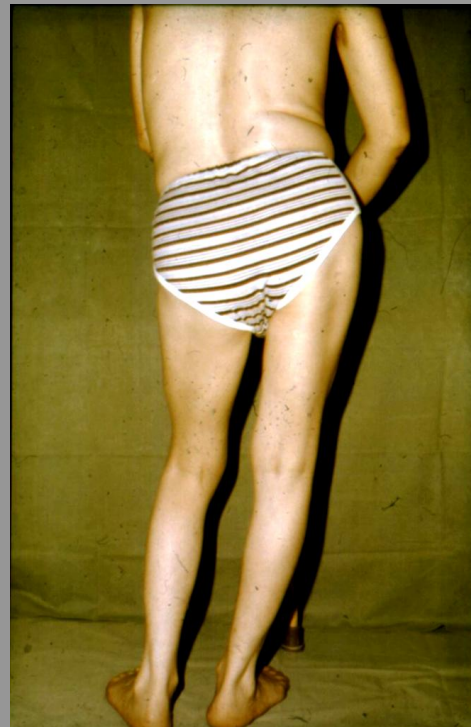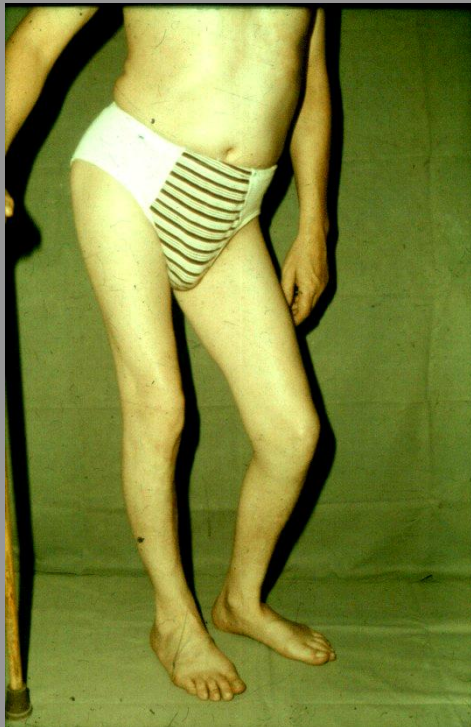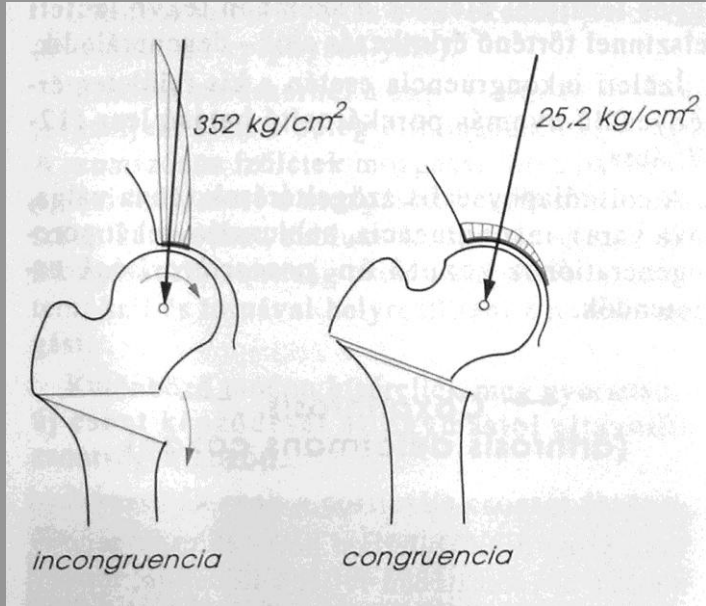
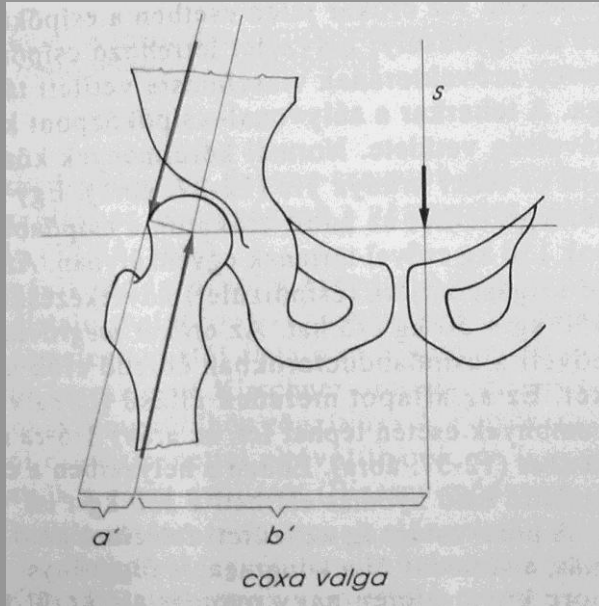
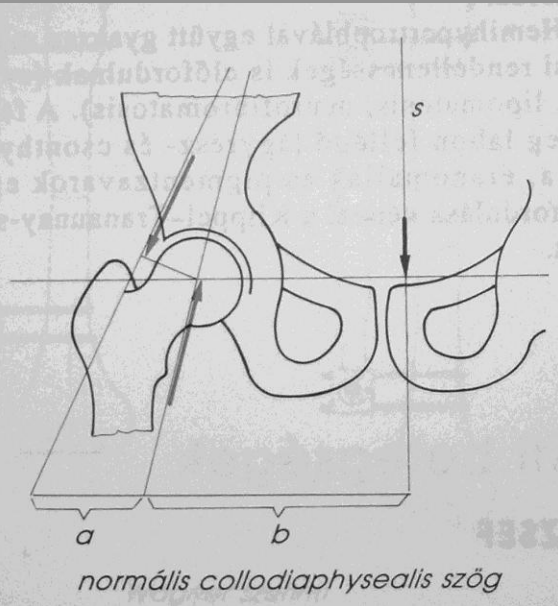
Osteoarthritis of the hip. Aseptic necrosis of the femoral head. Replacement of joints.

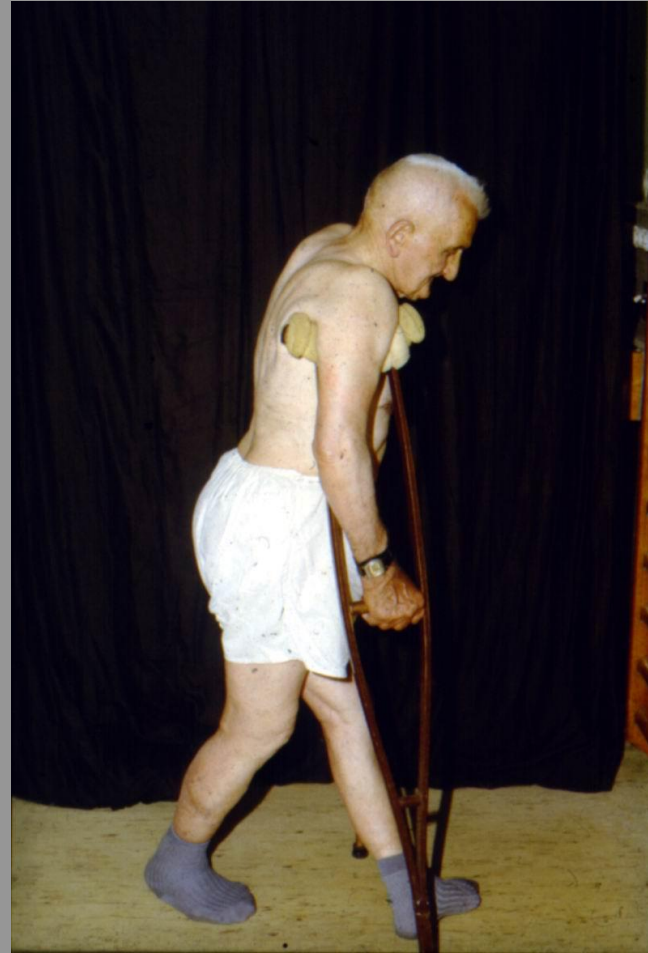
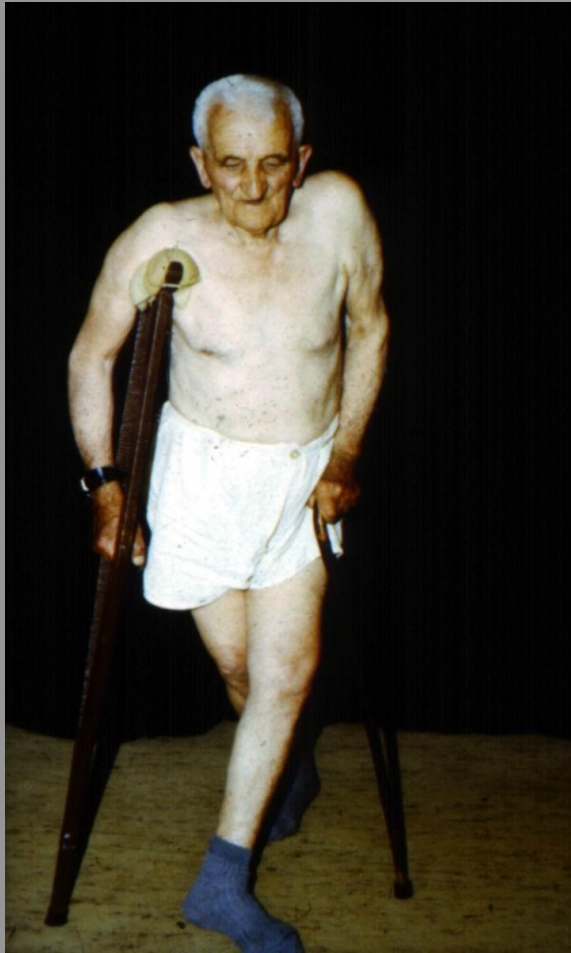

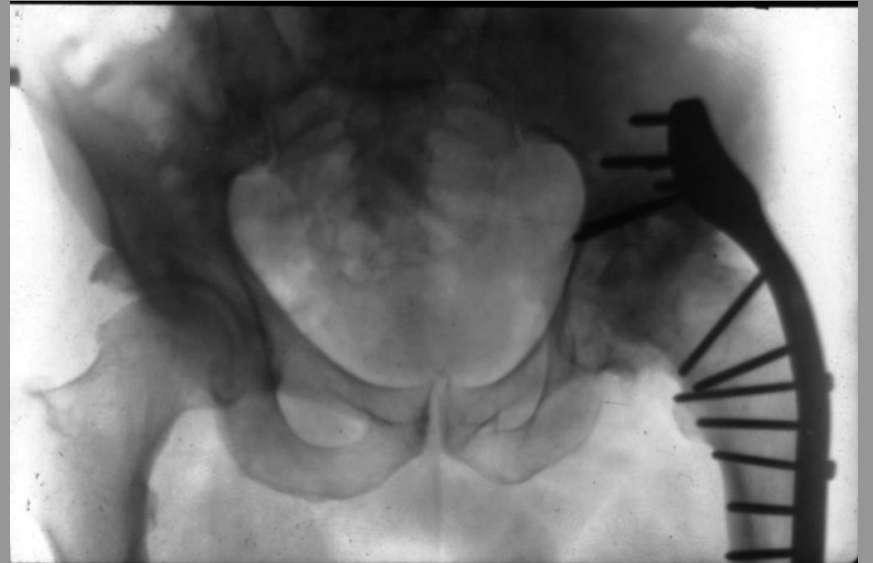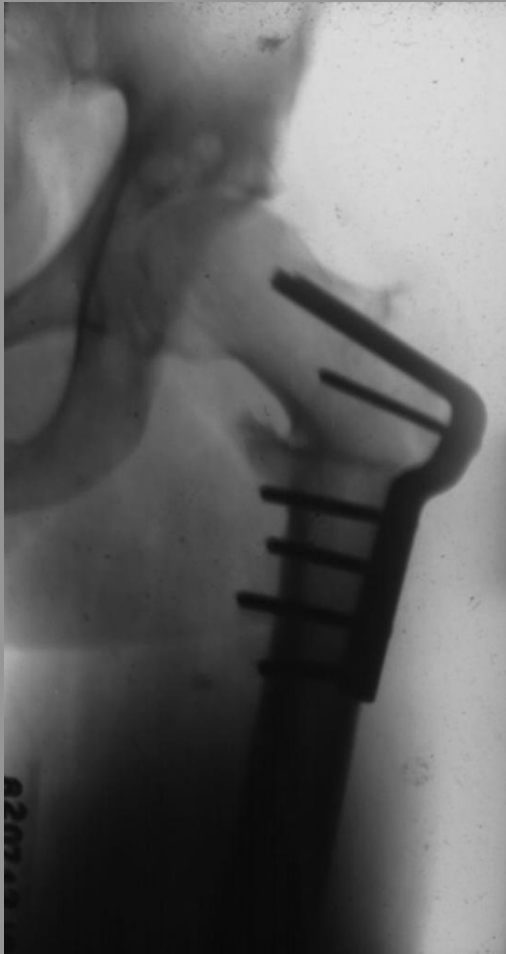**University of Debrecen
Department of
Orthopaedic Surgery**

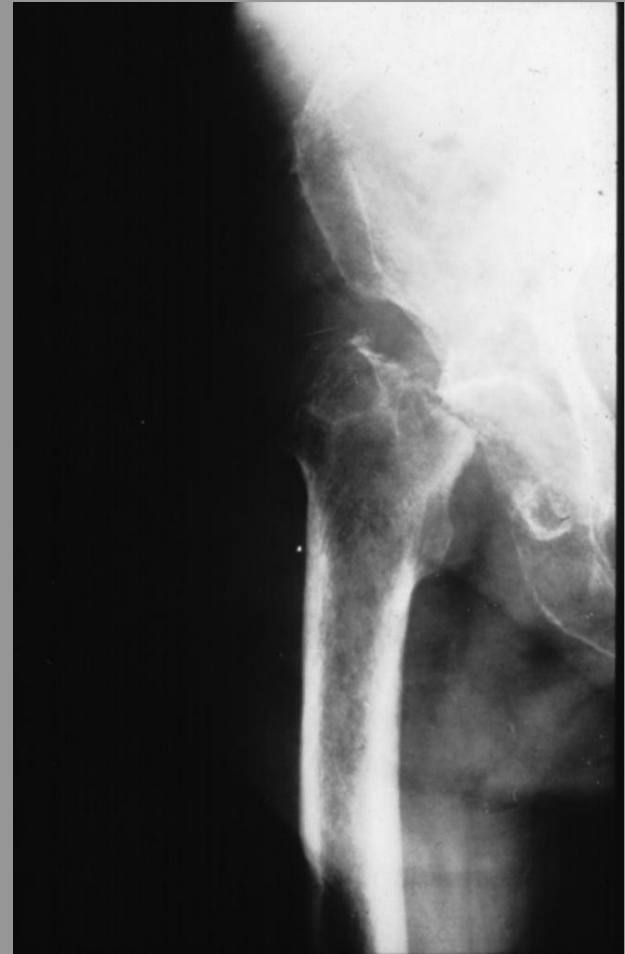
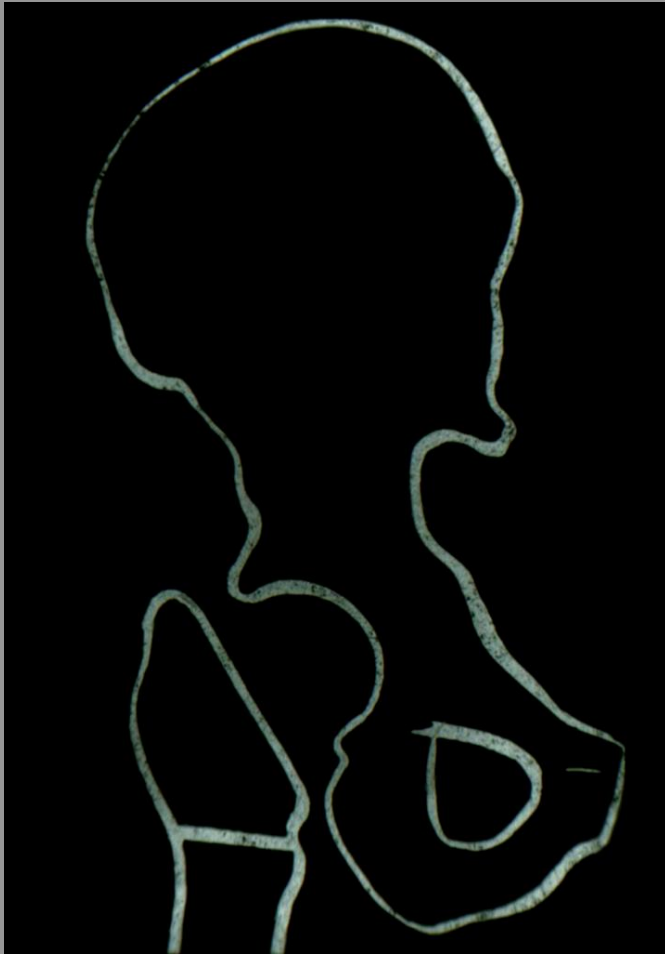


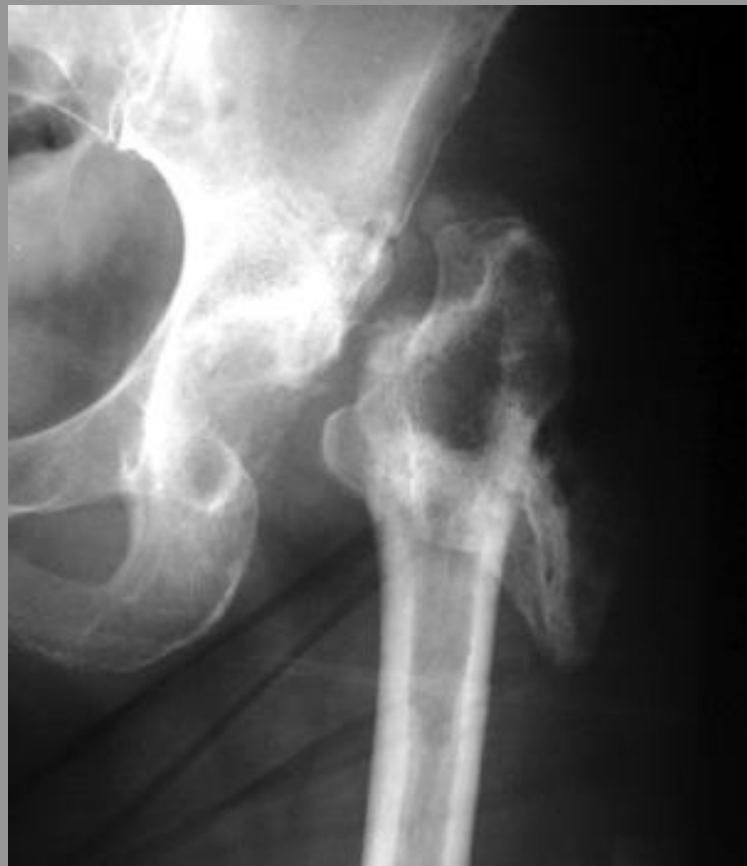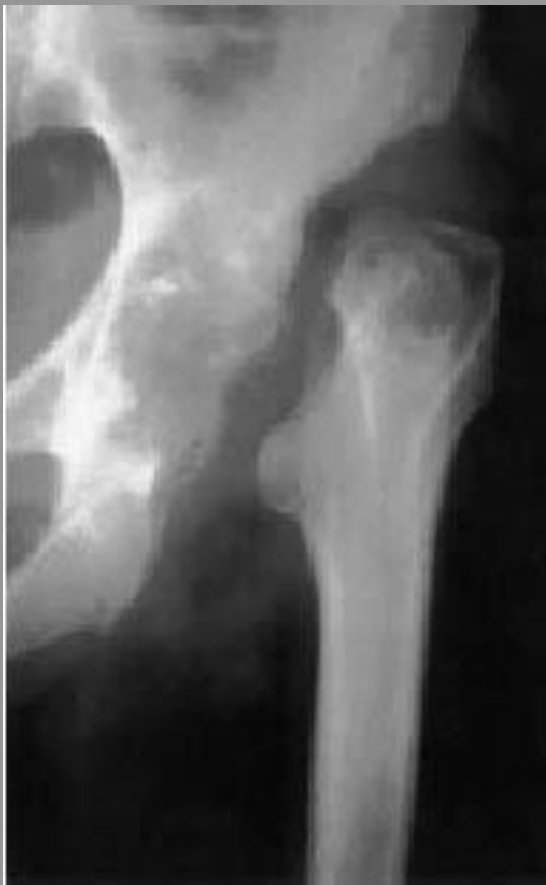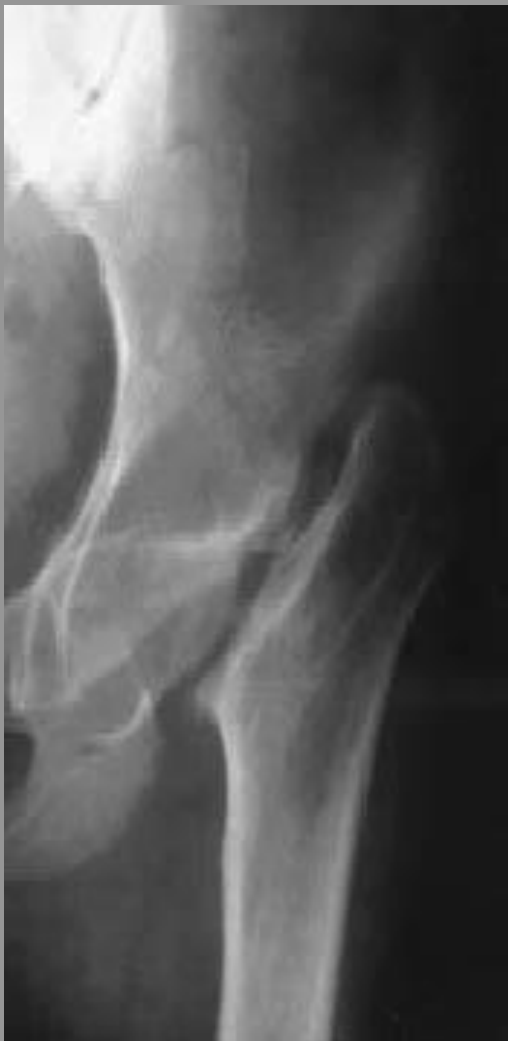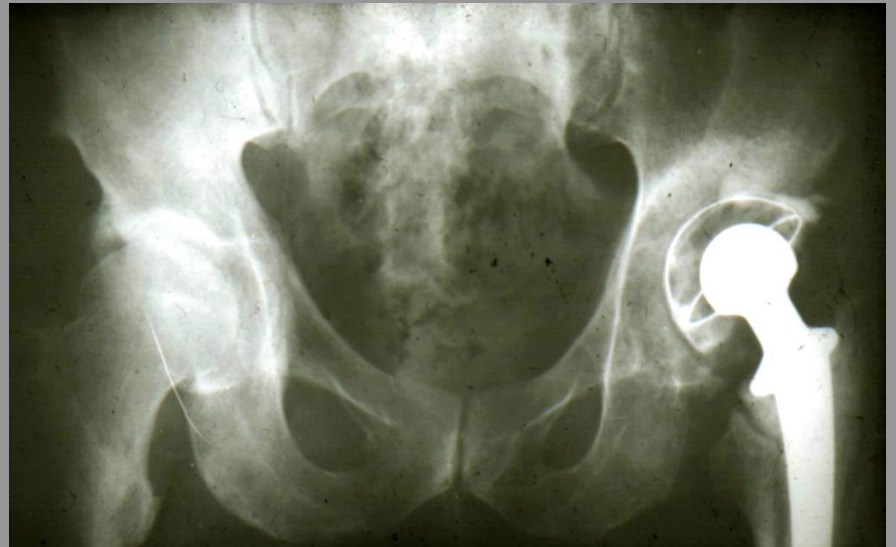



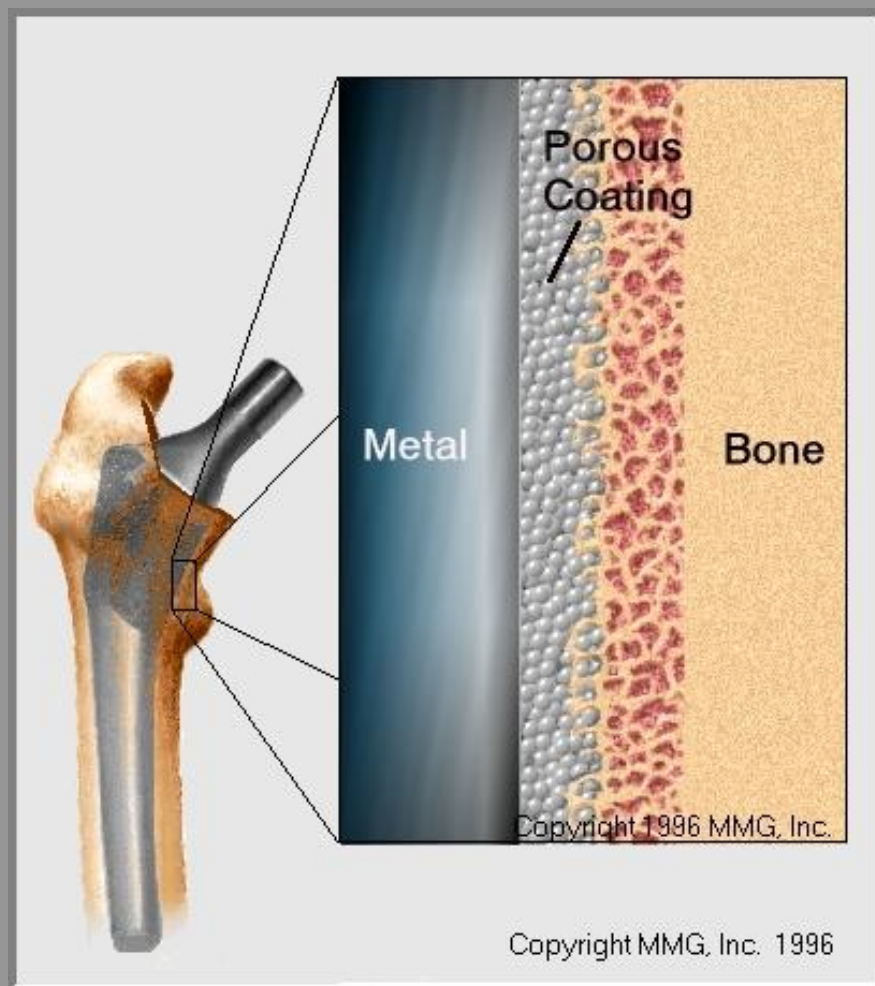
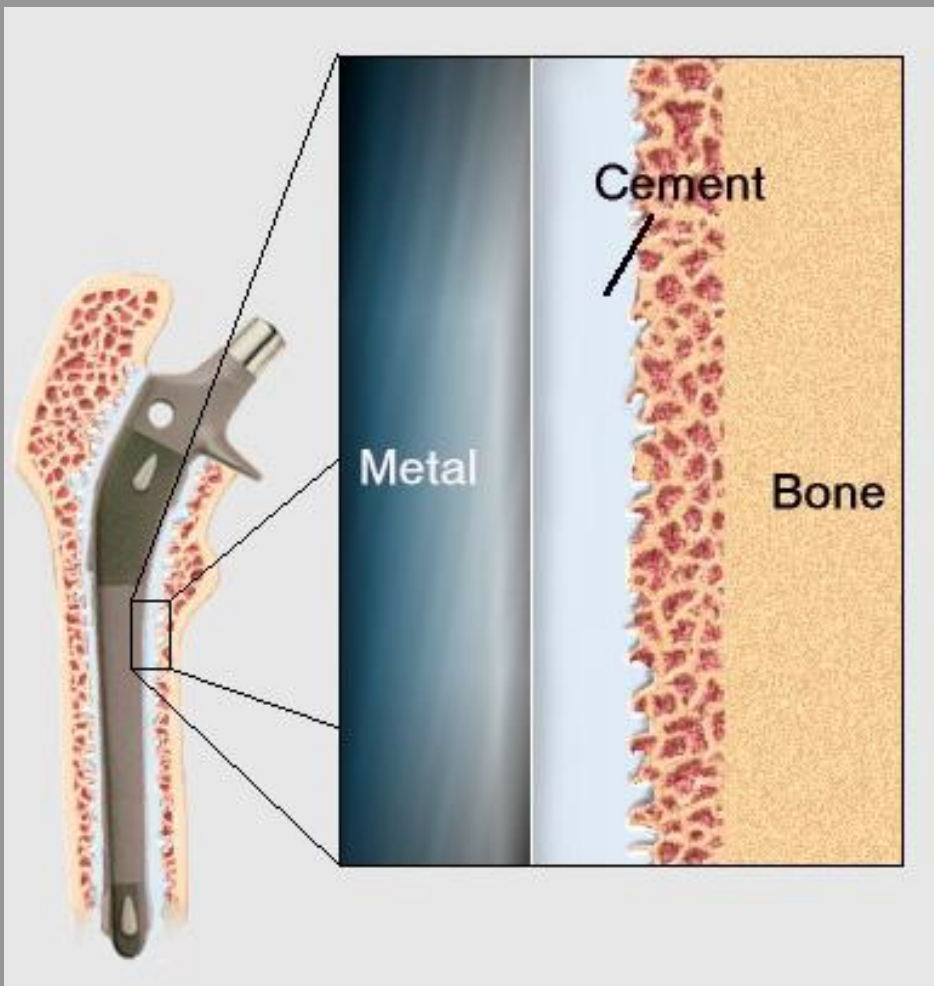




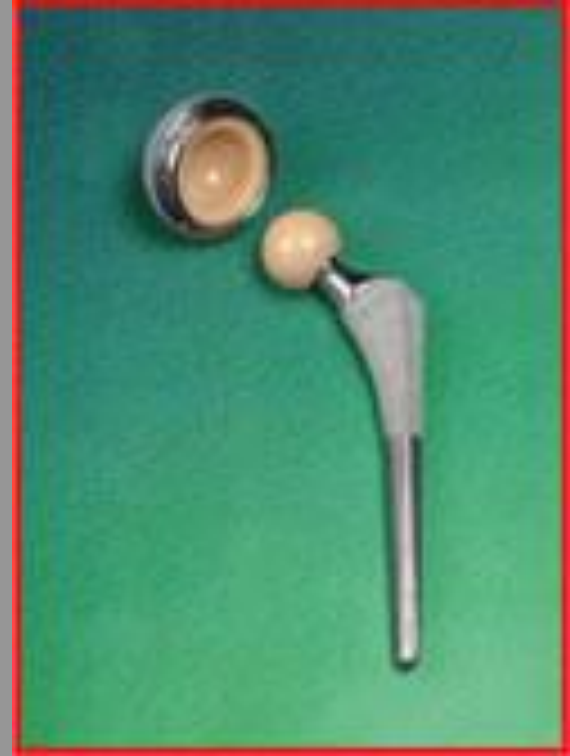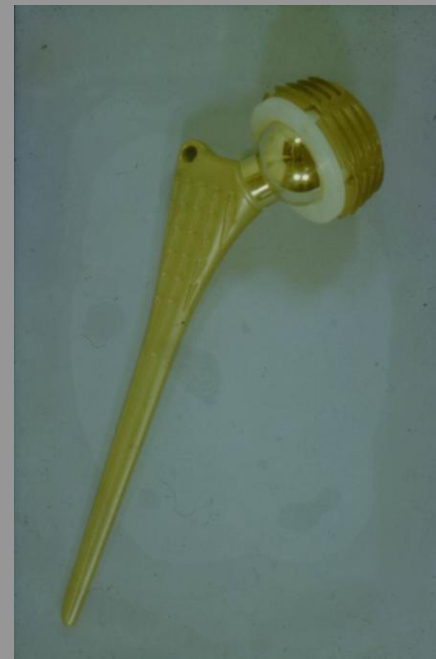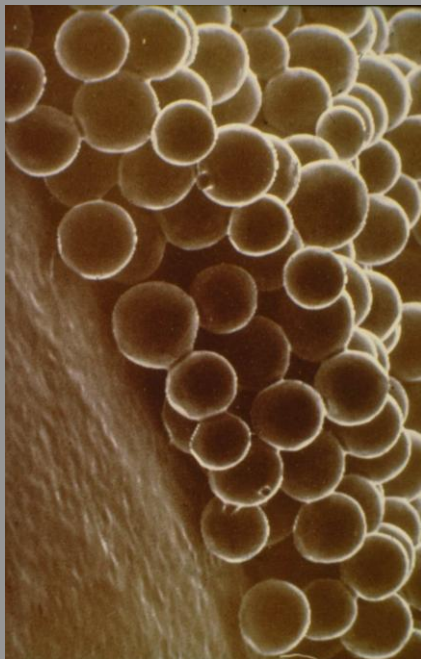



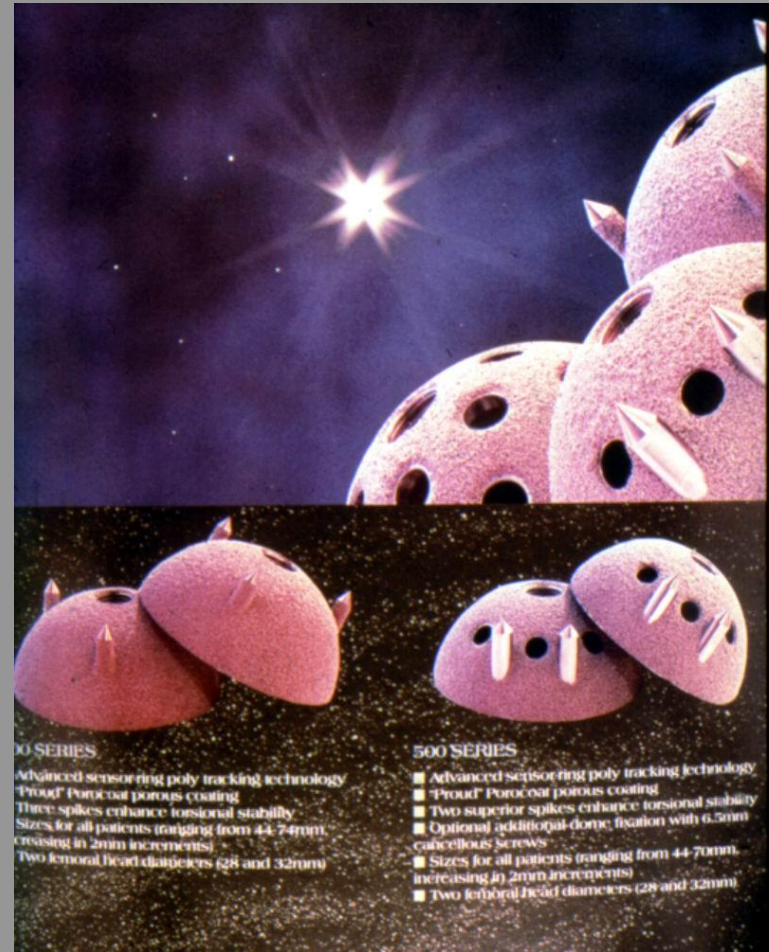
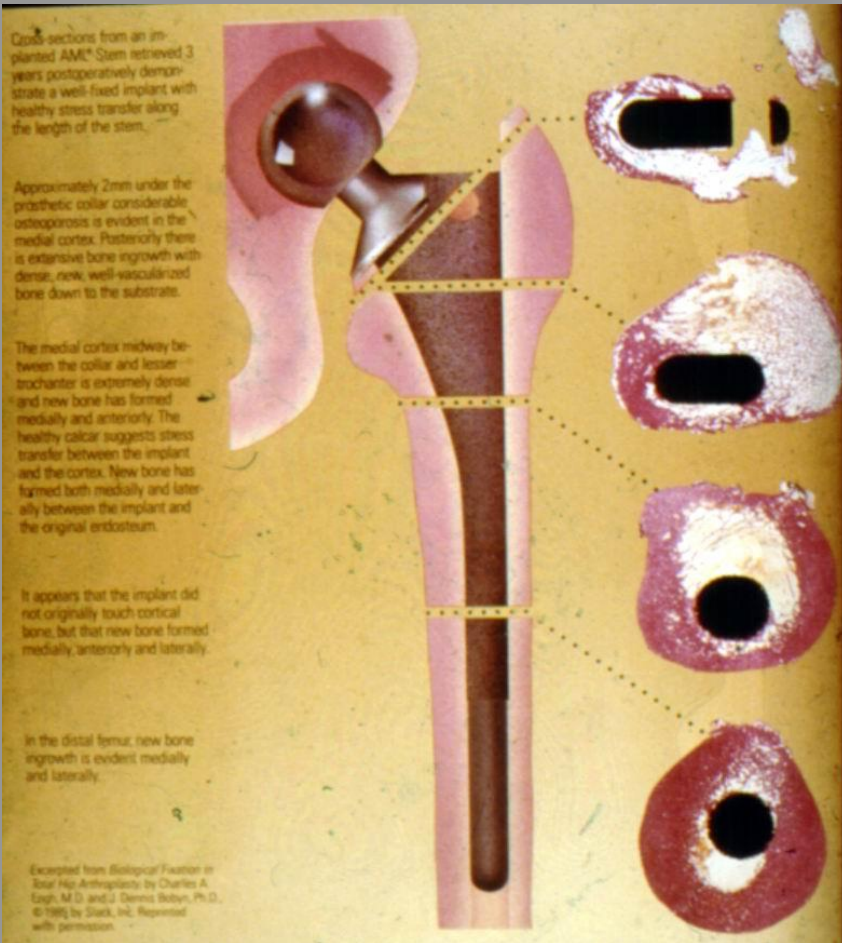


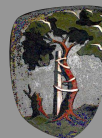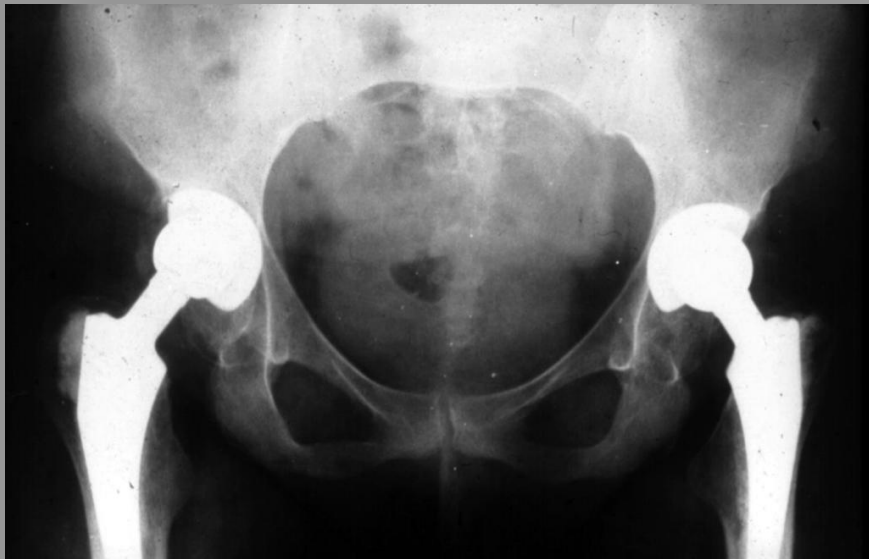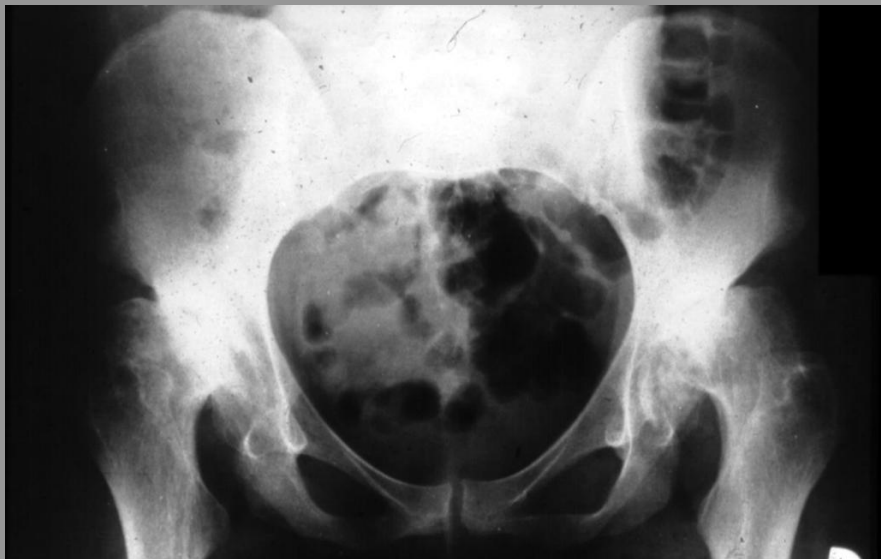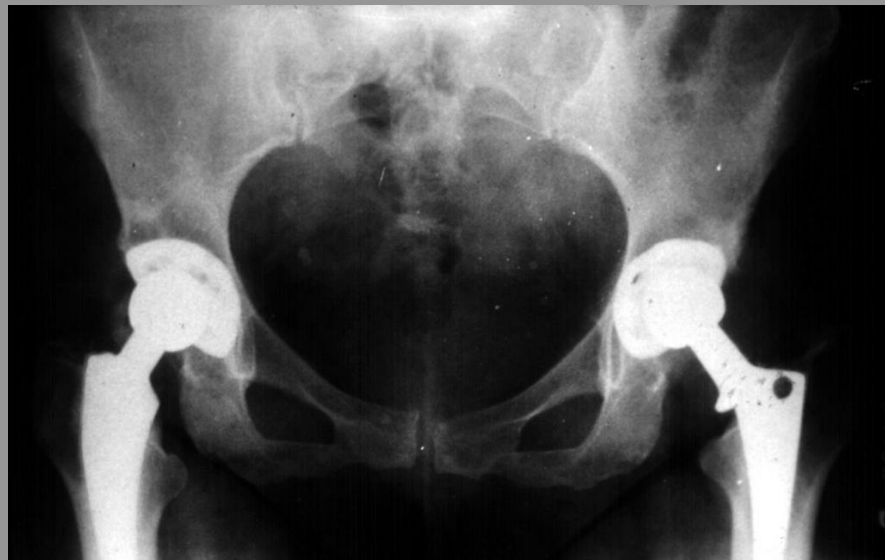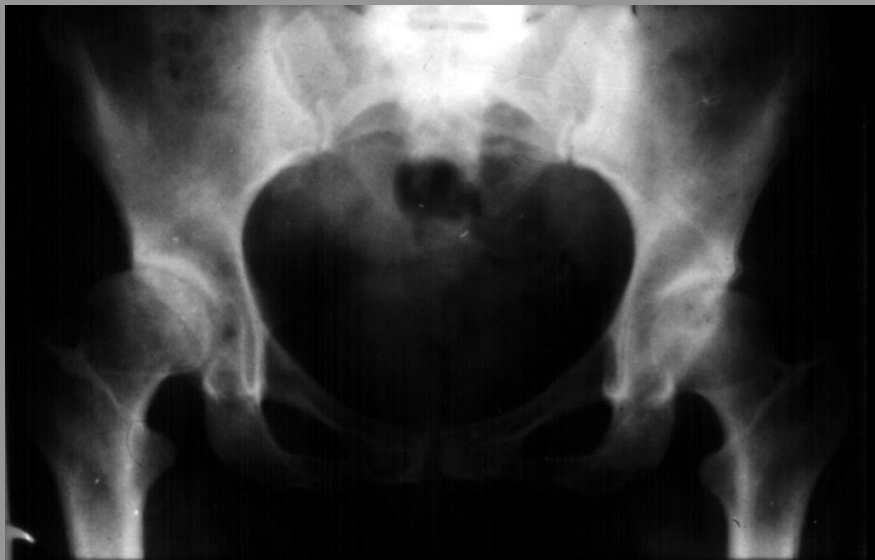




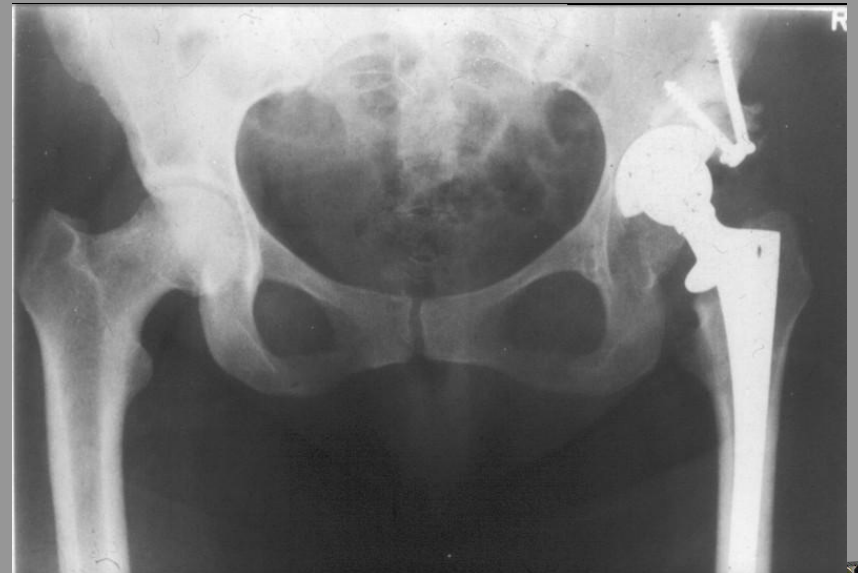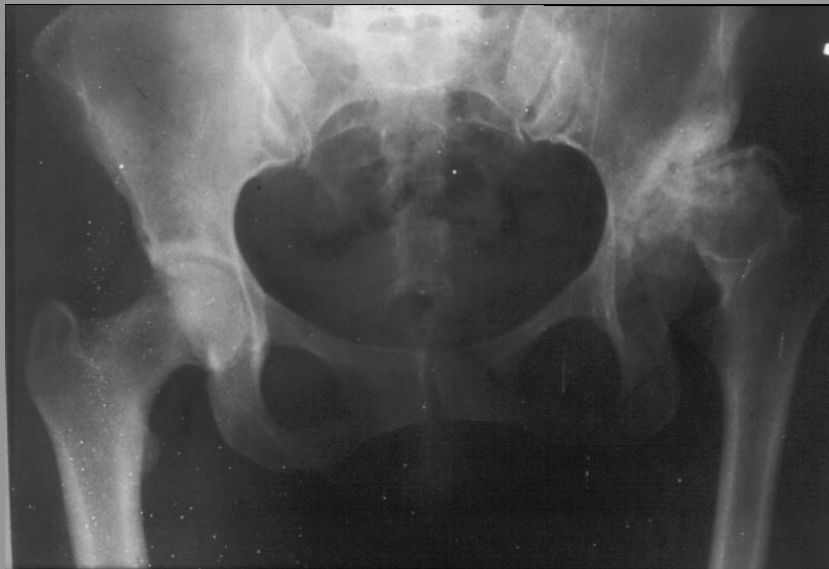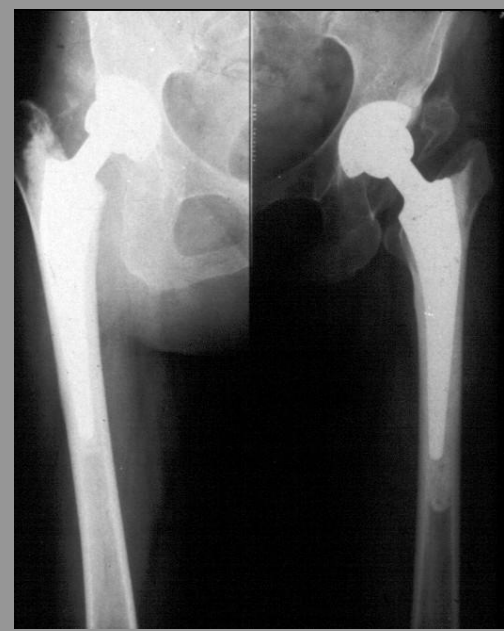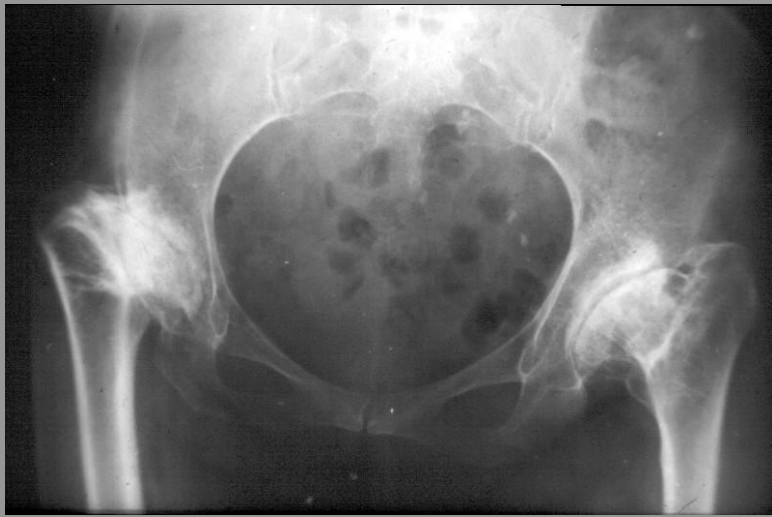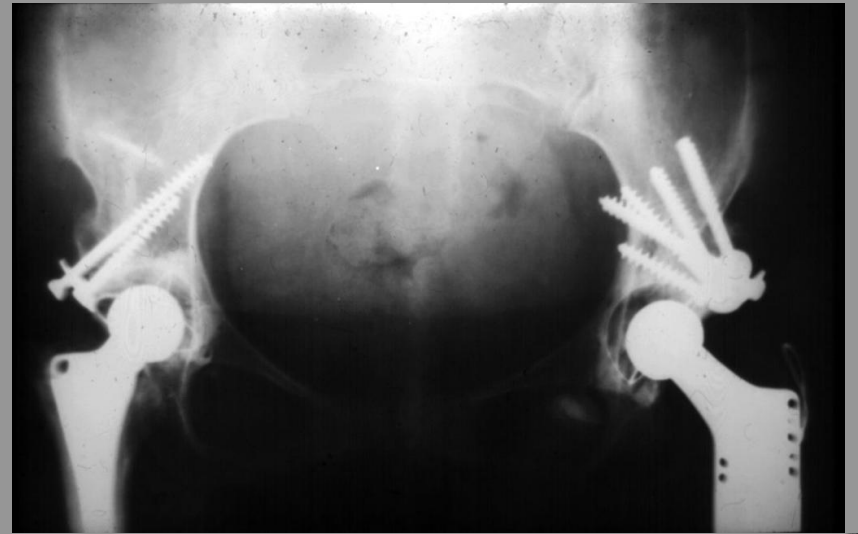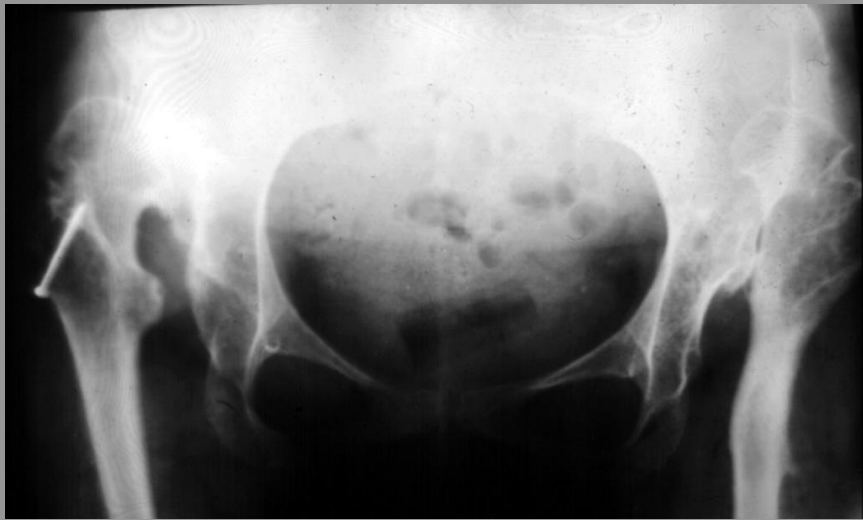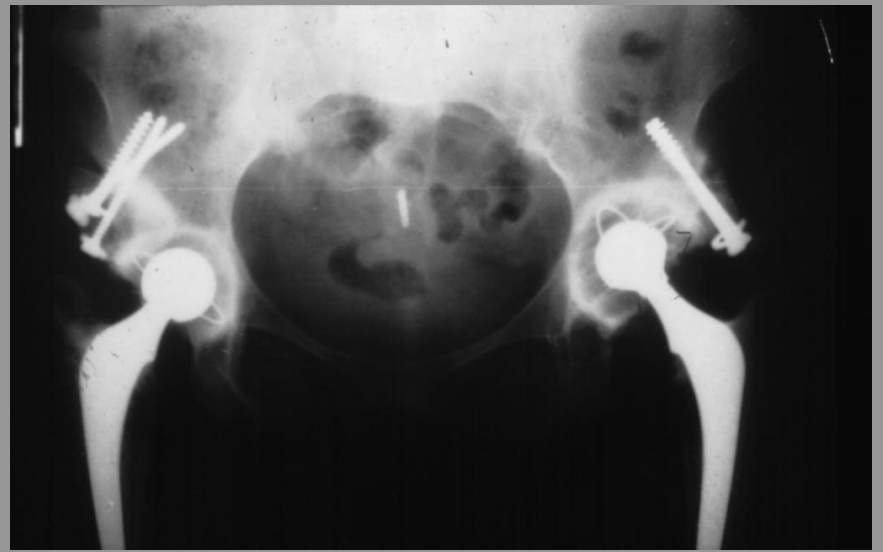
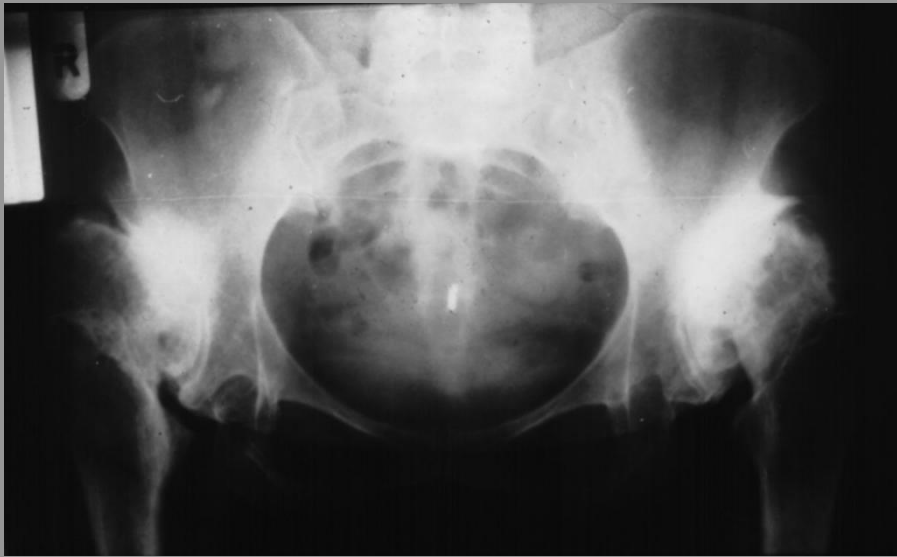


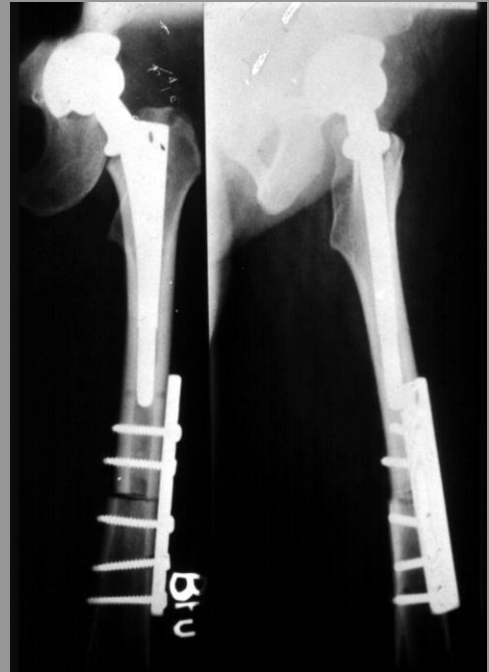
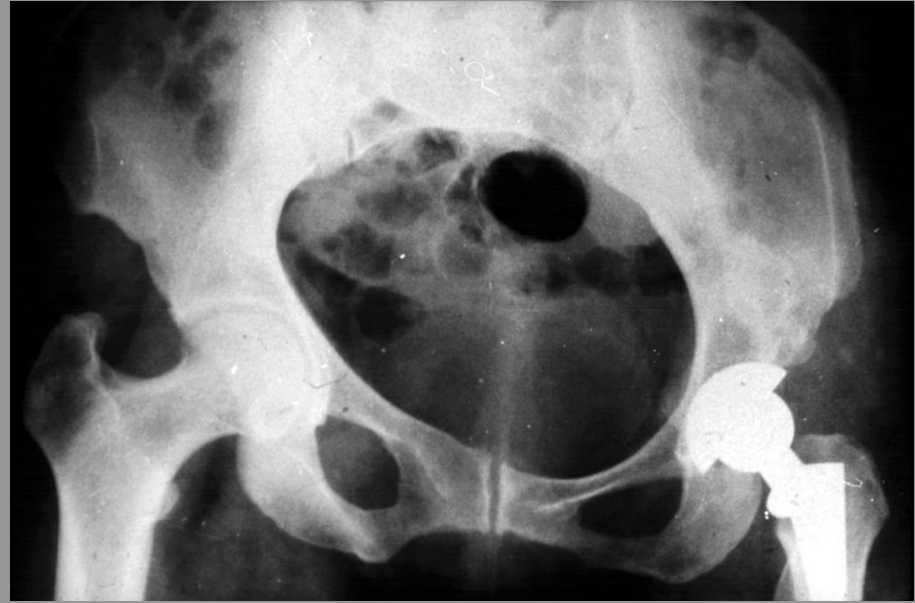


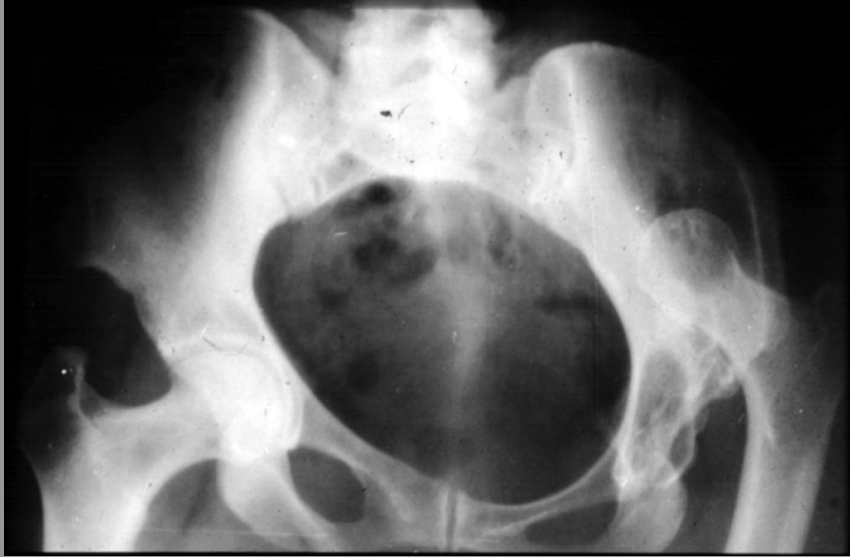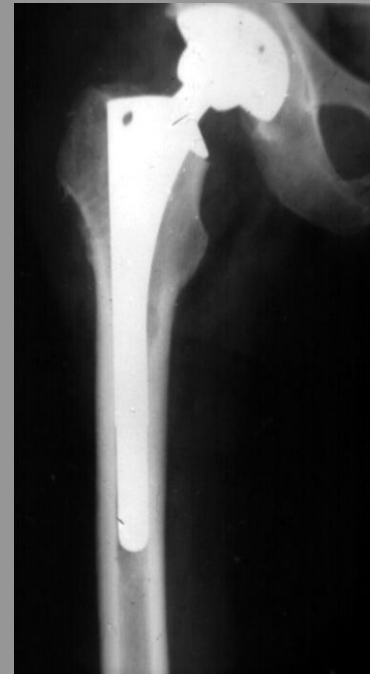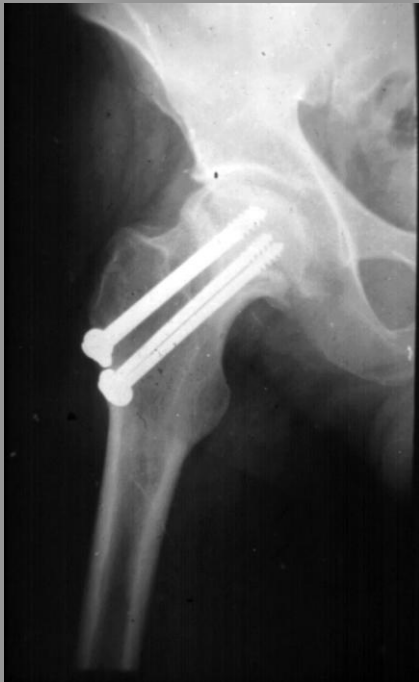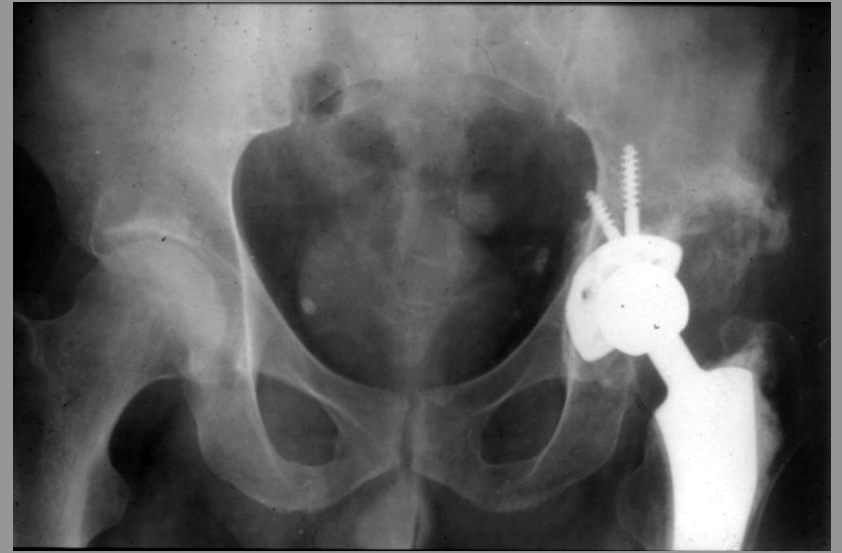











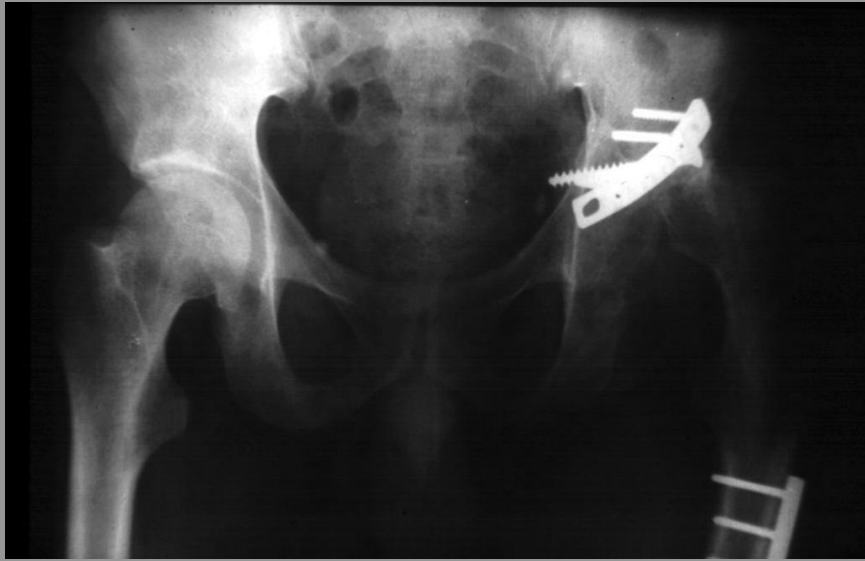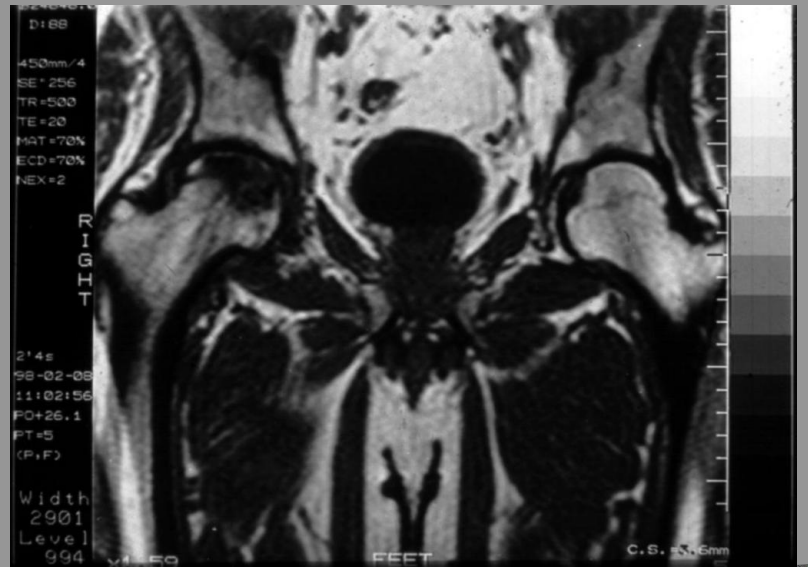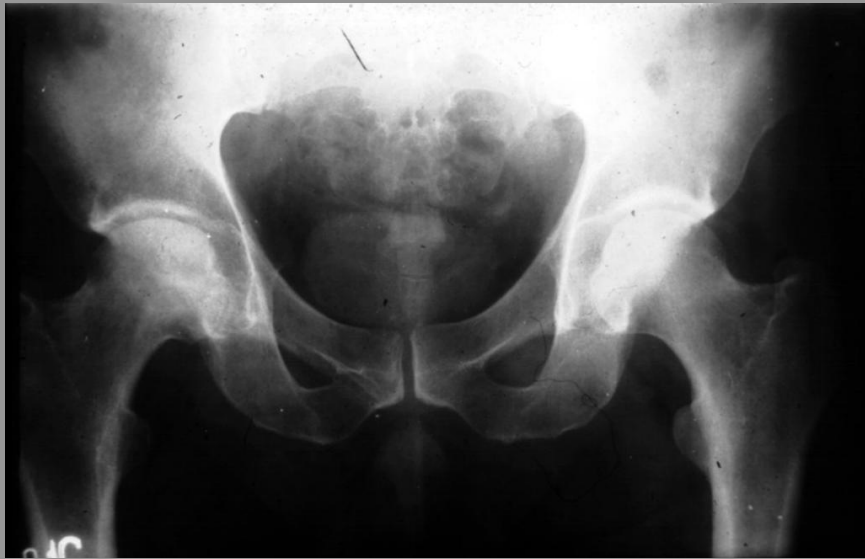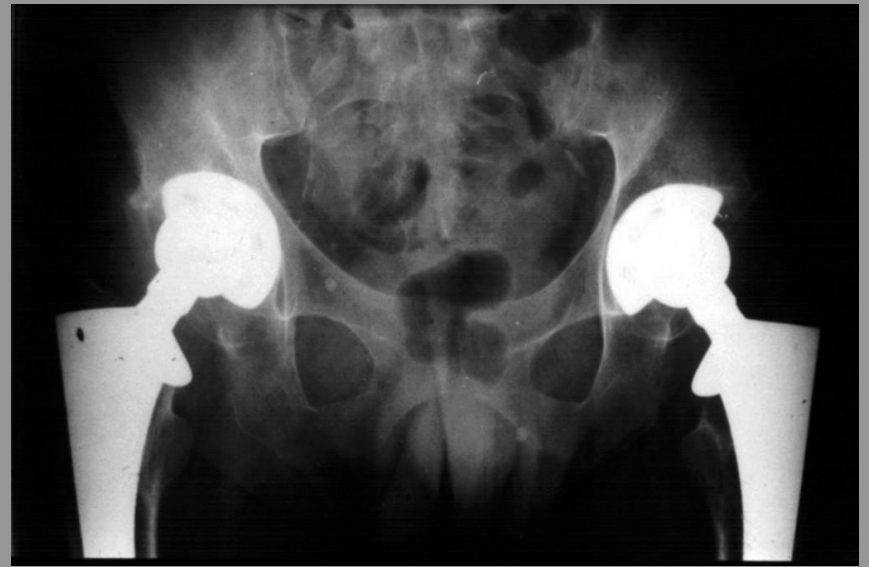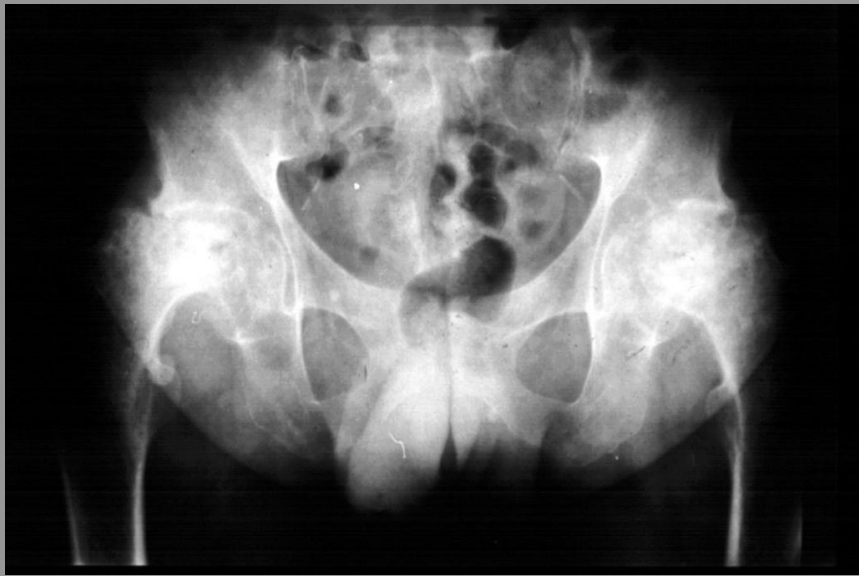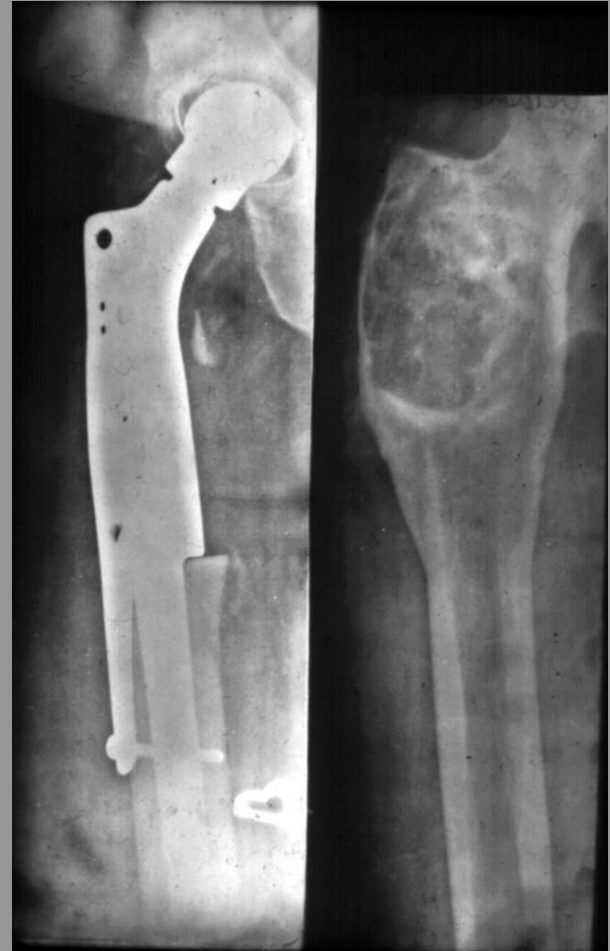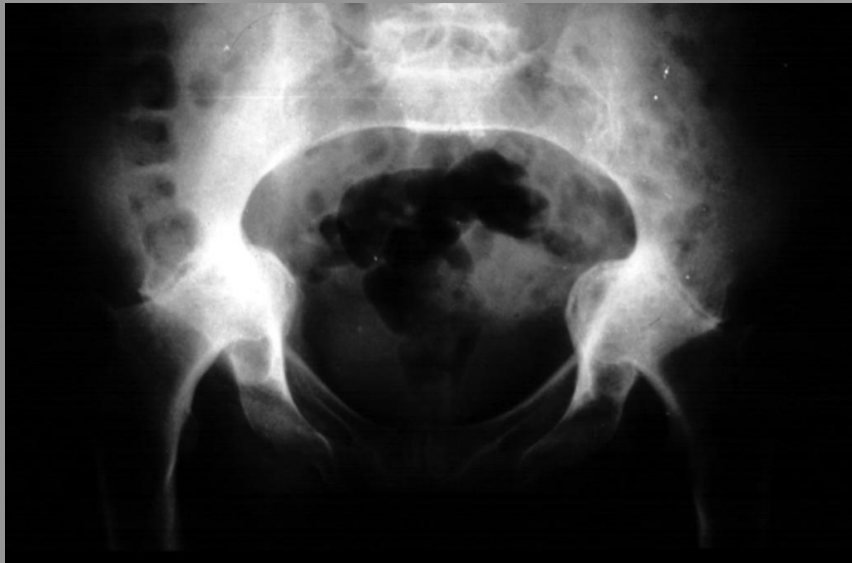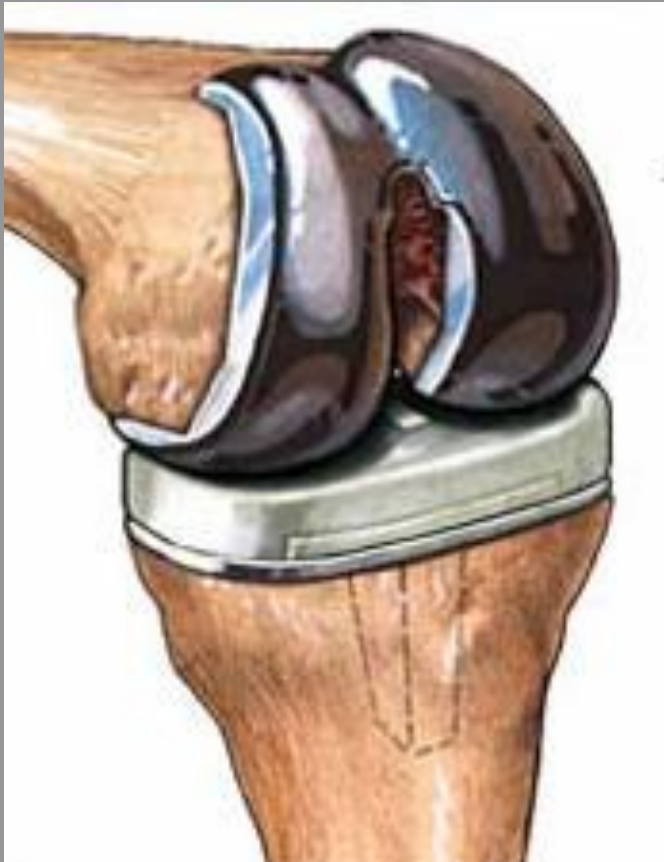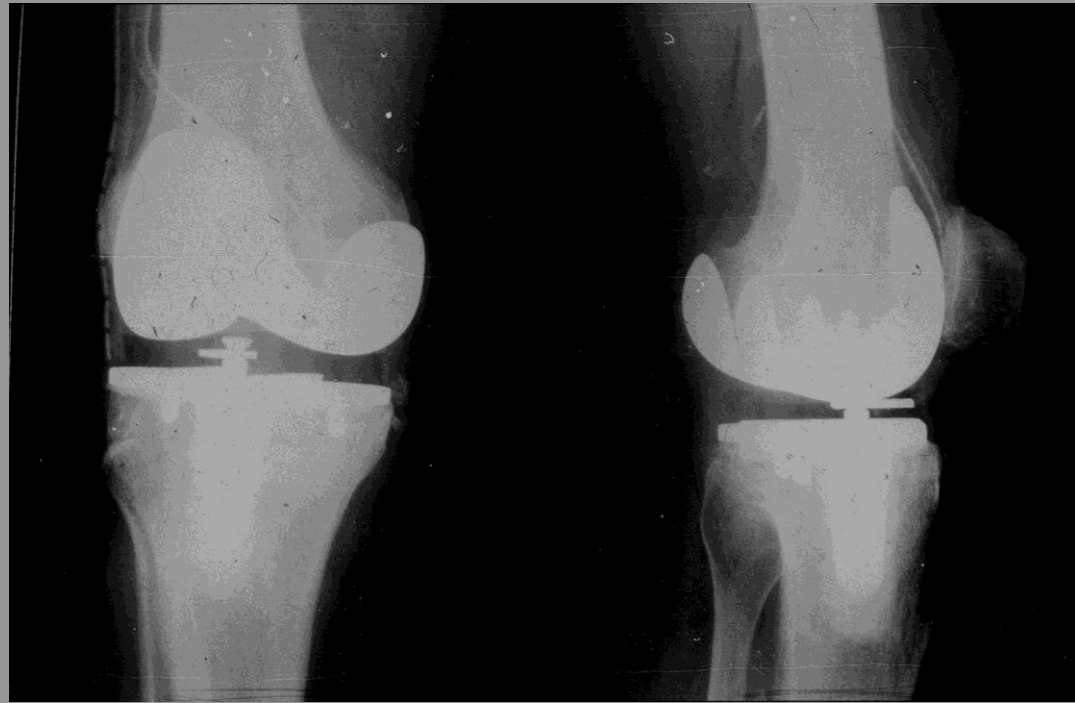


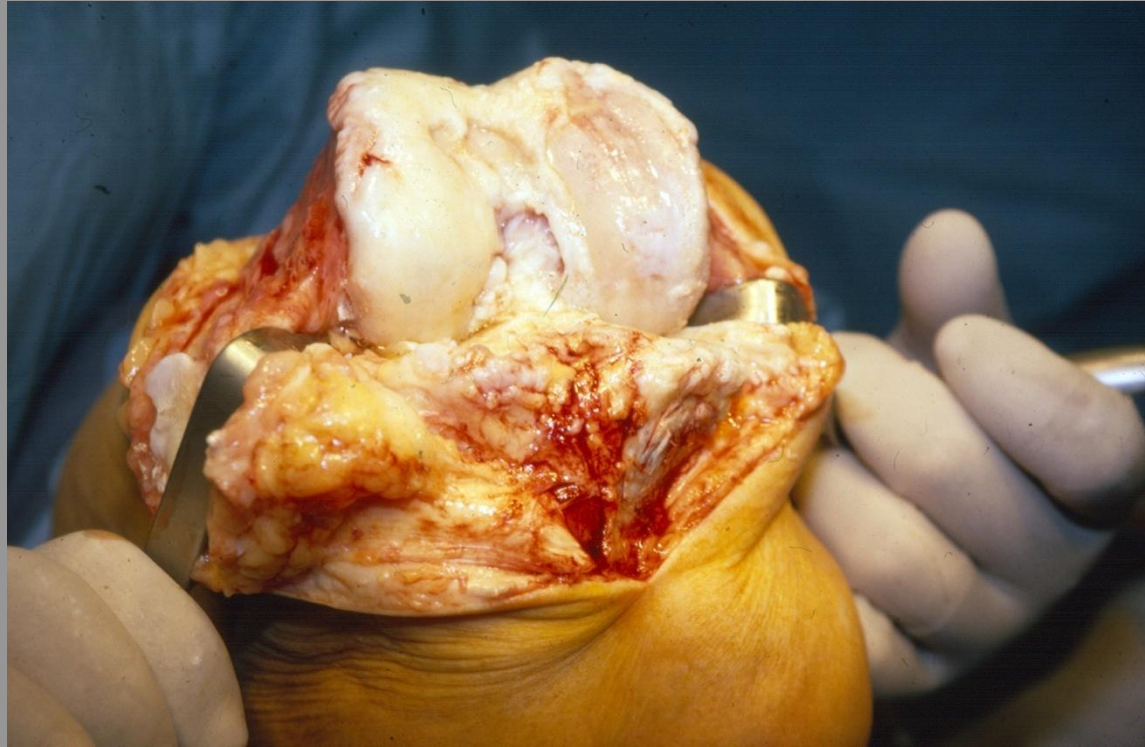


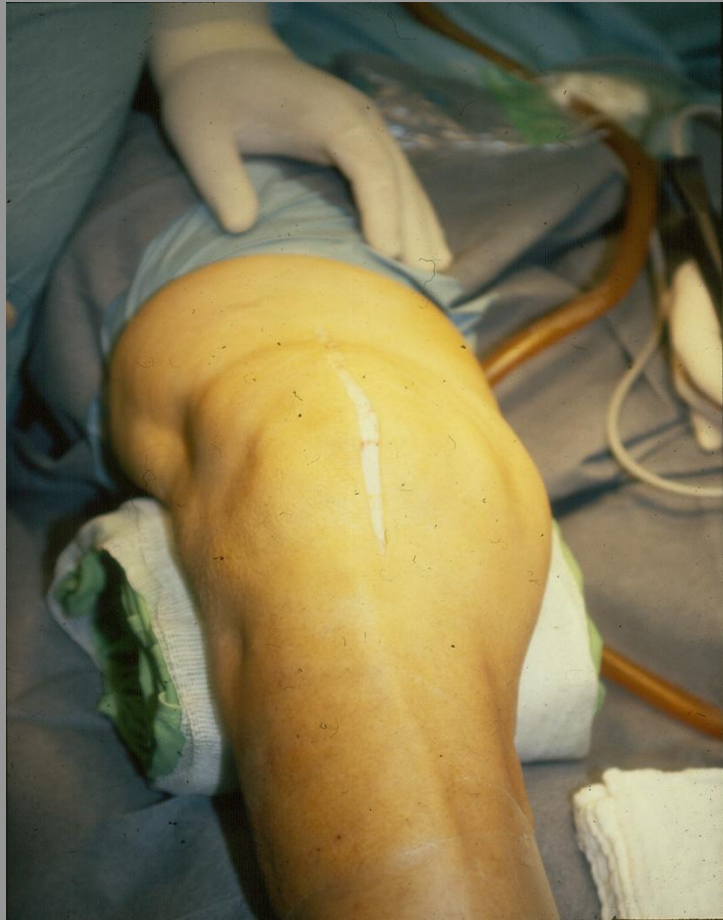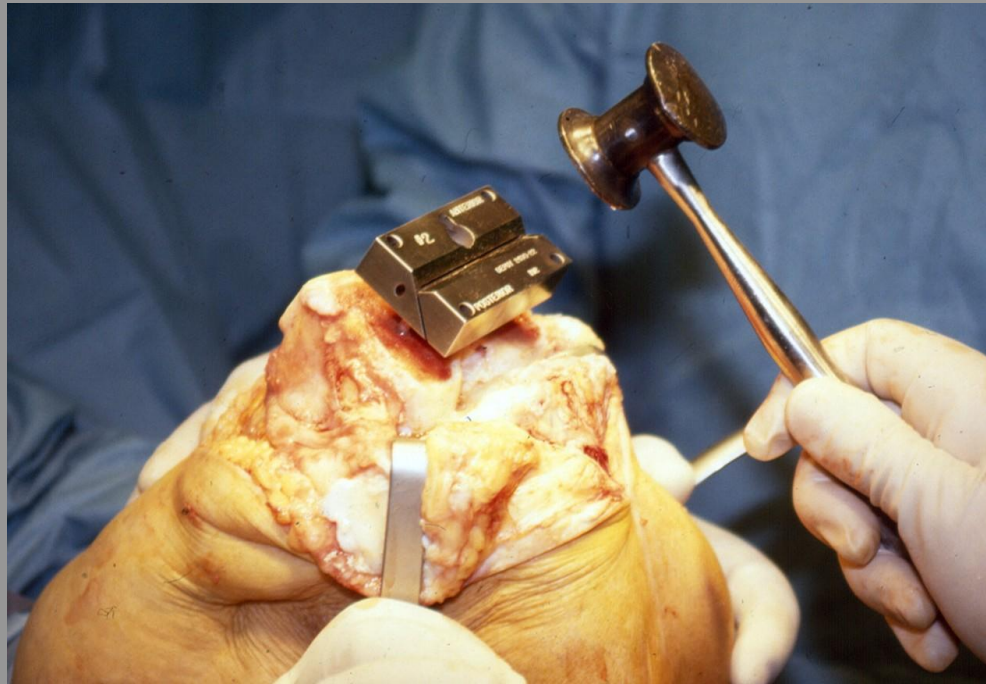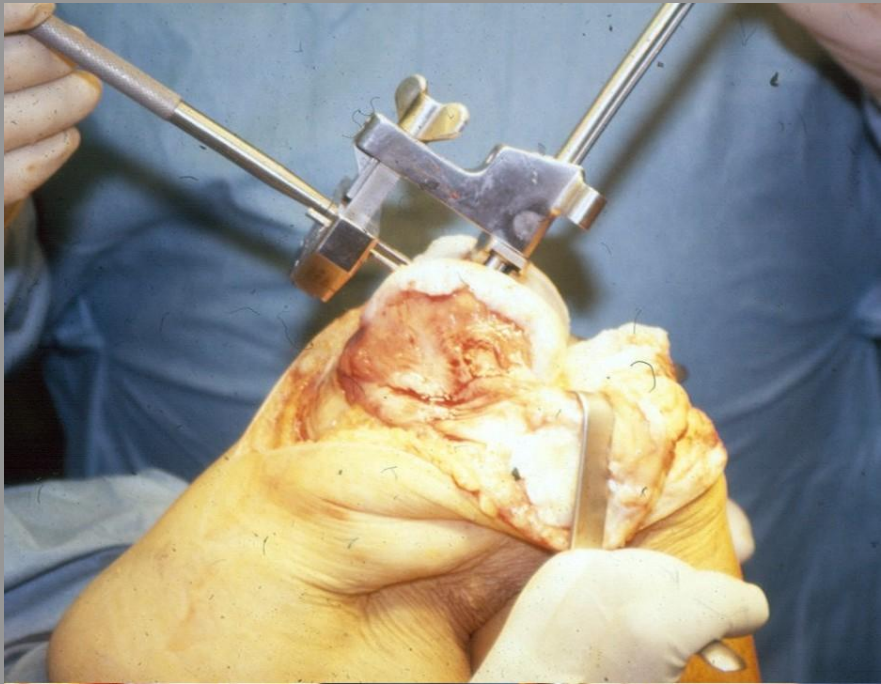


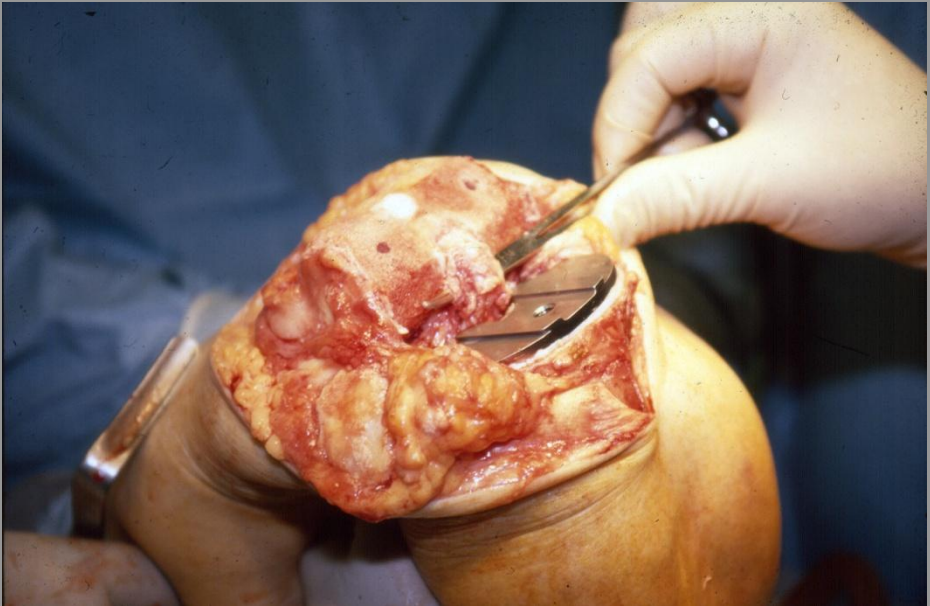
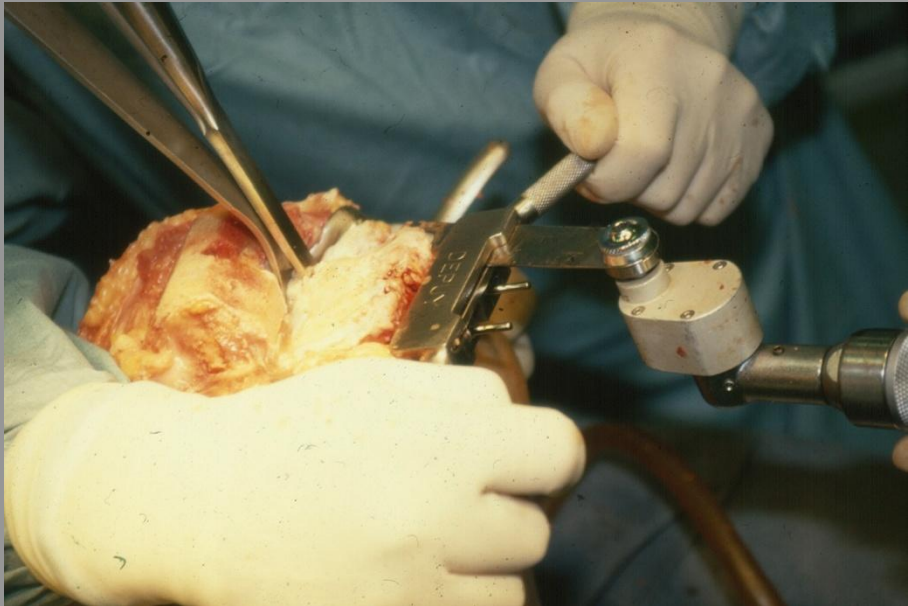


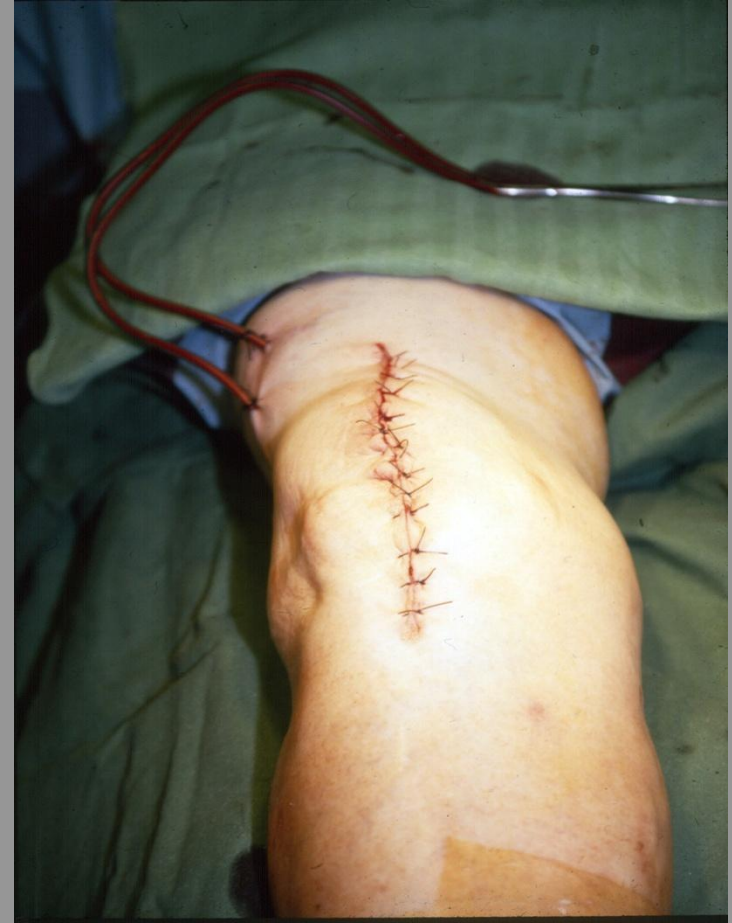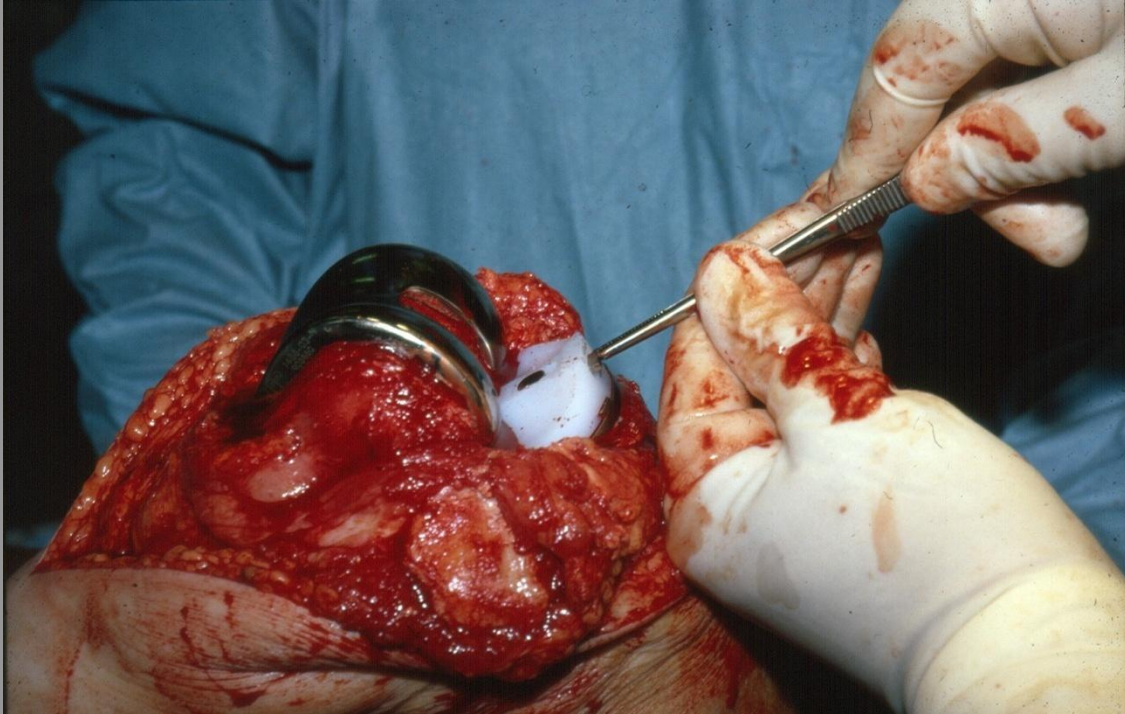


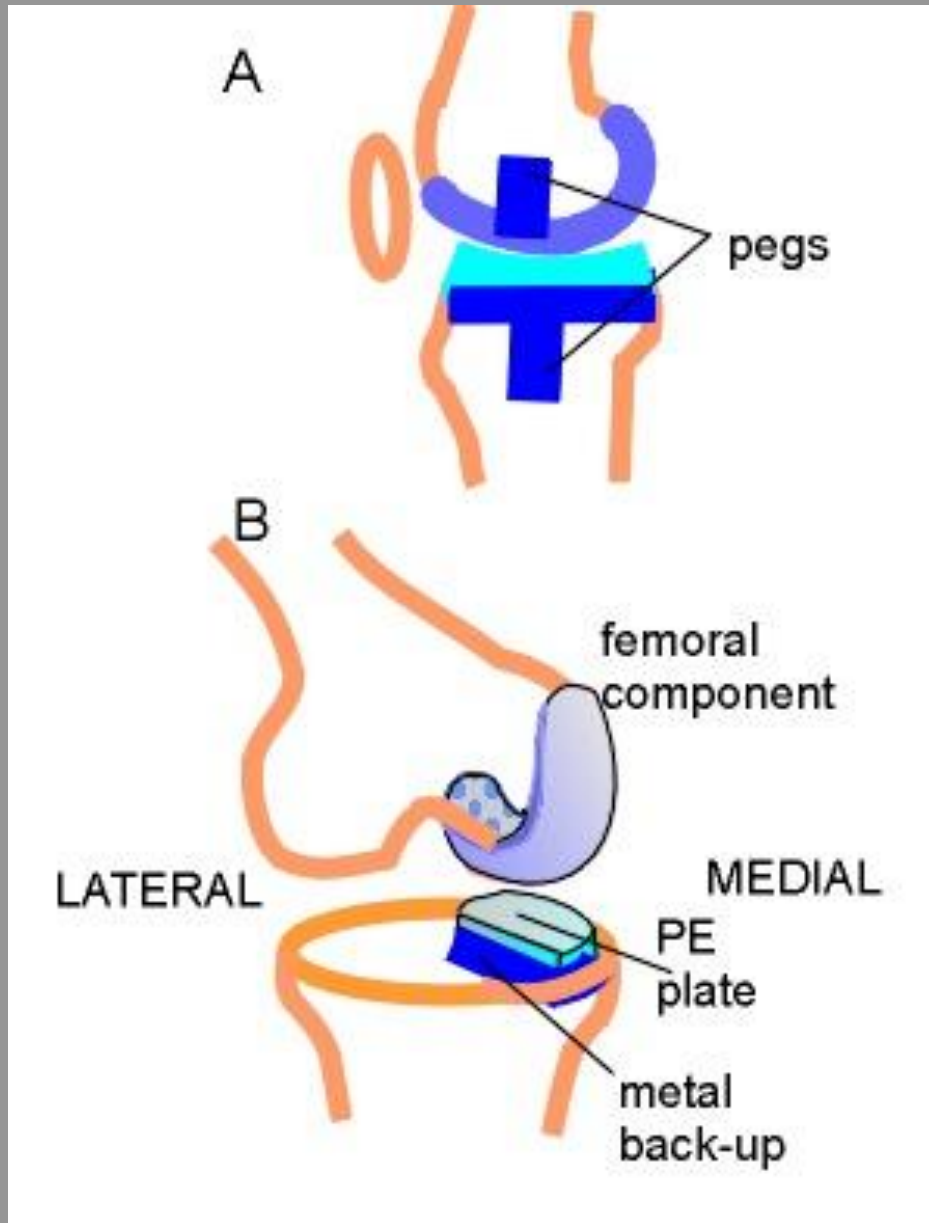












ORDER OF VERBAL EXAMS

The students are able to register for the exam on the NEPTUN system. The students pick two titles, from the title list available at the beginning of the Semester. This list can be also found on the web site of the Orthopaedic Department.

Those students who attended at least 70 % of the lectures will pick two titles, but will only be examined on the one of their choice.

In case of a B or C exam the student is not entitled to the above advantage.



